



Title	An approach to diagnosis of Jaagsiekte sheep retrovirus infection in sheep based on assessment of agreement between macroscopic examination, histopathologic examination and reverse-transcriptase polymerase chain reaction
Authors(s)	Lee, Alison Marie, Wolfe, Alan, Cassidy, Joseph P., Messam, Locksley L. McV., et al.
Publication date	2019-12
Publication information	Lee, Alison Marie, Alan Wolfe, Joseph P. Cassidy, Locksley L. McV. Messam, and et al. "An Approach to Diagnosis of Jaagsiekte Sheep Retrovirus Infection in Sheep Based on Assessment of Agreement between Macroscopic Examination, Histopathologic Examination and Reverse-Transcriptase Polymerase Chain Reaction." Elsevier, December 2019. https://doi.org/10.1016/j.smallrumres.2019.10.006 .
Publisher	Elsevier
Item record/more information	http://hdl.handle.net/10197/11323
Publisher's statement	This is the author's version of a work that was accepted for publication in Small Ruminant Research. Changes resulting from the publishing process, such as peer review, editing, corrections, structural formatting, and other quality control mechanisms may not be reflected in this document. Changes may have been made to this work since it was submitted for publication. A definitive version was subsequently published in Small Ruminant Research (VOL 181, (2019)) DOI: 10.1016/j.smallrumres.2019.10.006
Publisher's version (DOI)	10.1016/j.smallrumres.2019.10.006

Downloaded 2026-05-01 23:37:02

The UCD community has made this article openly available. Please share how this access benefits you. Your story matters! (@ucd_oa)



© Some rights reserved. For more information

Manuscript Number:

Title: An approach to diagnosis of Jaagsiekte sheep retrovirus infection in sheep based on assessment of agreement between macroscopic examination, histopathologic examination and reverse-transcriptase polymerase chain reaction.

Article Type: Research Paper

Keywords: Jaagsiekte sheep retrovirus, Neoplasms, Ovine Pulmonary Adenomatosis, Pathology, Polymerase chain reaction, Sheep

Corresponding Author: Miss Alison Marie Lee, MVB, B.Sc.

Corresponding Author's Institution: University College Dublin

First Author: Alison Marie Lee, MVB, B.Sc.

Order of Authors: Alison Marie Lee, MVB, B.Sc.; Alan Wolfe; Joseph P Cassidy; John Moriarty; Ronan O'Neill; Claire Fahy; Emily Connaghan; Chris Cousens; Mark P Dagleish; Maire C McElroy; Locksley L McV. Messam

Abstract: Jaagsiekte sheep retrovirus (JSRV) is the causative agent of ovine pulmonary adenocarcinoma (OPA). JSRV infection is usually detected post-mortem by macroscopic and histological examination of lungs for lesions of OPA. Subsequently, the presence of JSRV may be confirmed using reverse-transcriptase polymerase chain reaction (RT-PCR) on tumour tissue. Our goal was to determine the most effective way of combining macroscopic and histological examination with reverse transcriptase PCR (RT-PCR) to detect JSRV infection post-mortem. Lungs of slaughtered sheep (n=369) with macroscopic lesions were examined macroscopically and histologically to identify lesions consistent with OPA, and subsequently subjected to RT-PCR for JSRV. Positive (Ppos) and negative (Pneg) agreements and Cohen's Kappa coefficient were calculated between RT-PCR and: 1) macroscopic examination; 2) histological examination; 3) macroscopic and histological examination combined in series, and; 4) in parallel. The highest Ppos was between macroscopic and histologic examination in parallel and RT-PCR (0.38). Conversely, Pneg for all combinations of RT-PCR and macroscopic and histological examinations was high (95-96%). All Kappa values were low (0.1-0.33). This indicates that macroscopic and histological examination combined in parallel is the most effective way to identify animals that should be tested using RT-PCR for JSRV. If a positive result is obtained on macroscopic examination and/or histological examination, RT-PCR should be carried out to ascertain the presence of JSRV. The high Pneg indicates that if a negative result is obtained on macroscopic and histological examination, RT-PCR testing is not merited, as the result is likely to be negative. This provides an evidence-base for the diagnosis of JSRV infection.

Highlights

Evidence-based guidelines for JSRV diagnosis using OPA lesions have been provided

Macroscopic + histologic exam combined in parallel: Used to select lungs for RT-PCR

If macroscopic and histologic exam are both negative, JSRV RT-PCR is not required

If macroscopic and/or histologic exam are positive, JSRV RT-PCR is recommended

Approach may be applied to efficiently detect JSRV infection in a flock

1 **An approach to diagnosis of Jaagsiekte sheep retrovirus infection in sheep based on**
2 **assessment of agreement between macroscopic examination, histopathologic**
3 **examination and reverse-transcriptase polymerase chain reaction.**

4

5 Alison M. Lee^a, Alan Wolfe^a, Joseph P. Cassidy^a, John Moriarty^b, Ronan O'Neill^b, Claire
6 Fahy^b, Emily Connaghan^b, Chris Cousens^c, Mark P. Dagleish^c, Maire C. McElroy^b, Locksley
7 L. McV. Messam^a

8

9 ^aSchool of Veterinary Medicine, University College Dublin, Ireland. (alan.wolfe@ucd.ie,
10 joseph.cassidy@ucd.ie, locksley.messam@ucd.ie)

11 ^dDepartment of Agriculture, Food and the Marine Laboratories, Backweston Laboratory
12 Campus, Ireland. (john.moriarty@agriculture.gov.ie, ronan.oneill@agriculture.gov.ie,
13 claire.fahy@agriculture.gov.ie, emily.connaghan@agriculture.gov.ie,
14 mair.mcelroy@agriculture.gov.ie)

15 ^cMoredun Research Institute, Midlothian, Scotland. (mark.dagleish@moredun.ac.uk,
16 chris.cousens@moredun.ac.uk)

17

18 Corresponding author: Alison M. Lee, Room 009, Department of Veterinary Pathobiology,
19 Veterinary Science Centre, School of Veterinary Medicine, University College Dublin,
20 Belfield, Dublin 4, Ireland. Alison.lee@ucdconnect.ie

21

22

23 **Abstract**

24

25 Jaagsiekte sheep retrovirus (JSRV) is the causative agent of ovine pulmonary
26 adenocarcinoma (OPA). JSRV infection is usually detected post-mortem by macroscopic and
27 histological examination of lungs for lesions of OPA. Subsequently, the presence of JSRV
28 may be confirmed using reverse-transcriptase polymerase chain reaction (RT-PCR) on
29 tumour tissue. Our goal was to determine the most effective way of combining macroscopic
30 and histological examination with reverse transcriptase PCR (RT-PCR) to detect JSRV
31 infection post-mortem. Lungs of slaughtered sheep (n=369) with macroscopic lesions were
32 examined macroscopically and histologically to identify lesions consistent with OPA, and
33 subsequently subjected to RT-PCR for JSRV. Positive (P_{pos}) and negative (P_{neg}) agreements
34 and Cohen's Kappa coefficient were calculated between RT-PCR and: 1) macroscopic
35 examination; 2) histological examination; 3) macroscopic and histological examination
36 combined in series, and; 4) in parallel. The highest P_{pos} was between macroscopic and
37 histologic examination in parallel and RT-PCR (0.38). Conversely, P_{neg} for all combinations
38 of RT-PCR and macroscopic and histological examinations was high (95-96%). All Kappa
39 values were low (0.1-0.33). This indicates that macroscopic and histological examination
40 combined in parallel is the most effective way to identify animals that should be tested using
41 RT-PCR for JSRV. If a positive result is obtained on macroscopic examination and/or
42 histological examination, RT-PCR should be carried out to ascertain the presence of JSRV.
43 The high P_{neg} indicates that if a negative result is obtained on macroscopic and histological
44 examination, RT-PCR testing is not merited, as the result is likely to be negative. This
45 provides an evidence-base for the diagnosis of JSRV infection.

46 Keywords: Jaagsiekte sheep retrovirus, Neoplasms, Ovine Pulmonary Adenomatosis,
47 Pathology, Polymerase chain reaction, Sheep.

48

49 Funding: This research did not receive any specific grant from funding agencies in the public,
50 commercial, or not-for-profit sectors.

51

52

53

54

55

56

57

58

59

60

61

62

63

64

65

66 **Introduction**

67

68 Jaagsiekte Sheep Retrovirus (JSRV) is an oncogenic retrovirus that causes ovine pulmonary
69 adenocarcinoma (OPA), a progressive, fatal, bronchiolo-alveolar carcinoma of sheep
70 (Griffiths et al., 2015). Infection has been reported in various countries across Europe, Asia,
71 Africa and South and North America (Griffiths, 2015). Evidence indicates that JSRV is
72 transmitted primarily via the respiratory route but transmission via colostrum and milk may
73 also play a role (Grego et al., 2008; Griffiths et al., 2015). Clinical disease is most commonly
74 reported in adult animals and signs include dyspnoea, tachypnoea, condition loss, nasal
75 discharge and coughing (Griffiths et al., 2015). After initial introduction of the virus into a
76 flock, mortality rates may be as high as 30-50% but decrease to 1-5% as the disease becomes
77 endemic (Griffiths et al., 2015). It is likely that owners of infected flocks suffer financial
78 losses due to reduced body weights, early culling and increased mortality. Additionally, the
79 welfare of animals suffering from advanced clinical disease is compromised. Given the long
80 incubation period (months-years) and the difficulty in accurately diagnosing animals in the
81 early stages of OPA, the infection is likely highly underreported (Scott et al., 2013).

82 Knowledge of a flock's infection status is important, as farmers can undertake various
83 methods to control the disease, thus improving production and animal welfare (Scott et al.,
84 2013). A recent survey in Ireland established a preliminary estimate of prevalence of JSRV
85 infection and OPA as 1.6% and 0.5% respectively in Irish sheep (Lee et al., 2017). A similar
86 survey in the UK found an OPA prevalence of 0.9% in adult sheep (Cousens et al., 2015).
87 While the prevalence is therefore likely low, certain flocks have a higher prevalence than
88 others, meaning these flocks are likely disproportionately affected by the virus (Lee et al,
89 2017). Therefore, an economically viable, evidence-based method for identifying infected
90 flocks is necessary for disease control.

91 Post-mortem examination, including both macroscopic pathology and histopathology
92 frequently plays a role in disease prevalence surveys and control programmes. Post-mortem
93 macroscopic examination (ME) for the detection of the typical macroscopic lung lesions of
94 OPA followed up with histologic examination (HE) for OPA lesions is currently the standard
95 method of diagnosing JSRV infection within an individual animal or flock (Scott et al.,
96 2013). However, ME will not detect animals that are infected with JSRV but have not yet
97 developed OPA as it is impossible to detect the presence of JSRV based on pathologic
98 changes alone, and routine post-mortem examination may not detect small, early stage
99 lesions. Additionally, lesions of OPA may be obscured by concurrent pathology (e.g.
100 bronchopneumonia, lungworm). Therefore, ME and HE are not without limitations.

101

102 Polymerase chain reaction (PCR) on suspect neoplastic lung tissue for JSRV are sometimes
103 used as an aid to post-mortem examination. In the diagnostic setting, this is mainly used as a
104 follow-up test to confirm equivocal cases based on the assumption of a high sensitivity and
105 specificity when performed on OPA tumour tissue (Scott et al., 2013). However, there is, to
106 the authors' knowledge, no evidence-based information as to how PCR should be combined
107 with ME and HE to optimise post-mortem detection of JSRV infection in the literature. This
108 information is vital for diagnostic accuracy as well as for optimising management of
109 resources.

110

111 The goal of this study was to determine an optimal way of using ME and HE along with
112 reverse-transcriptase PCR (RT-PCR) in order to detect JSRV infection post-mortem. This
113 provides a diagnostic evidence base to assist veterinary pathologists and veterinarians in their
114 application and interpretation of macroscopic and histological post-mortem findings.

115 **Materials and Methods**

116

117 The study population consisted of 369 adult (over one year old) lowland and highland breeds
118 of sheep slaughtered at an Irish abattoir between September and November 2015, as
119 described elsewhere (Lee et al., 2017). The sheep originated from 127 Irish flocks in 18
120 counties with the majority being cull ewes. No animals were slaughtered specifically for the
121 purposes of this study.

122

123 Subsequent to slaughter and evisceration, lungs were selected for further examination (ME,
124 HE and RT-PCR), by visual examination and palpation at the abattoir over the course of ten
125 separate visits in September-November 2015. A team of 2 - 3 veterinarians were responsible
126 for initial lung examination and selection on each visit; these included first author (AML)
127 accompanied by veterinarians from the Department of Agriculture, Food and the Marine
128 (DAFM) experienced in post-mortem examination of farm animals. All lungs displaying
129 significant macroscopic lesions of any type were selected for further examination. Most lungs
130 displayed numerous subpleural, dark red, pinpoint foci due to aspiration of blood at slaughter
131 and those with only this change were excluded from the study.

132

133 After initial selection, lungs were subject to ME and categorised according to the gross
134 appearance of the lesions present as previously described (Lee et al., 2017). These categories
135 included abscesses, cranioventral consolidation, discolouration, fibrosis, focal firm nodule(s),
136 mineralisation, subpleural parasitic granulomas, macroscopic suspect OPA, uncollapsed
137 lungs and other lesions that did not fit into the aforementioned categories (i.e. other). The
138 macroscopic changes characterising each category have been described in detail previously

139 (Lee et al., 2017) and the above-mentioned categories were based on commonly described
140 pathologic changes found in sheep lungs (Caswell and Williams, 2016). A section of tissue
141 approximately one cm³ was taken from each pulmonary lesion at the border between the
142 lesion and normal tissue, where possible. These samples were processed routinely for
143 histology and stained with haematoxylin and eosin (H&E). Also during ME, a smaller portion
144 of tissue (0.5 cm³) was taken from the pulmonary lesions directly adjacent to the site sampled
145 for histology and subjected to real-time RT-PCR for JSRV. Sample preservation, nucleic acid
146 extraction and the RT-PCR protocol was carried out according to standard procedure as
147 described previously (Lee et al., 2017). Macroscopic examination and HE was carried out by
148 AML and RT-PCR was carried out by EC (co-author). A diagnosis of JSRV infection (based
149 the presence of macroscopic OPA lesions) on ME was constituted by locally extensive, well-
150 demarcated, consolidated, heavy, oedematous, grey-purple areas (Caswell and Williams,
151 2016). A diagnosis of JSRV infection (based on the presence of histologic OPA lesions) on
152 HE was constituted by single or multifocal, well-demarcated-infiltrative tumours with
153 papillary/lepidic/acinar growth patterns consisting of cuboidal-columnar cells supported by a
154 fine fibrous stroma and surrounded by macrophage infiltration (Caswell and Williams, 2016).
155 On RT-PCR, test samples with a cycle threshold value of < 38 were considered positive for
156 JSRV. Only sheep positive for JSRV on RT-PCR were considered to be infected with JSRV,
157 regardless of what macroscopic or histopathologic lesions were present.

158

159 Measures of agreement were calculated for the following pairs of tests: ME and RT-PCR, HE
160 and RT-PCR, ME and HE combined in series (ME-HE_{series}) and RT-PCR, and ME and HE
161 combined in parallel (ME-HE_{parallel}) and RT-PCR (Table 1). If two tests are combined *in*
162 *series* to diagnose a condition, a positive result on *both* tests must be obtained for the overall
163 result to be considered positive (Figure 1A). If two tests are combined *in parallel* to diagnose

164 the same condition, a positive result on *one or both* tests is sufficient for the overall result to
 165 be considered positive (Figure 1B). In the context of this study, the two diagnostic procedures
 166 combined in series or in parallel are considered to be one diagnostic test. Measures of
 167 agreement calculated included positive agreement (P_{pos}) and negative agreement (P_{neg}) using
 168 Microsoft Excel 2010. Positive agreement is the number of positive results that both tests
 169 agree on expressed as a proportion of the average number of positive results obtained from
 170 both tests. Similarly, P_{neg} is the number of negative results that both tests agree on expressed
 171 as a proportion of the average number of negative results obtained from both tests (Cicchetti
 172 and Feinstein, 1990). Standard errors (SE) of P_{pos} and P_{neg} for construction of approximate
 173 95% confidence intervals (CIs) were derived using the Delta method (Oehlert, 1992)
 174 exploiting their correspondence with Chamberlain's P_{pos} and P_{neg} (Cicchetti and Feinstin,
 175 1990). Formulae for calculations were as follows, based on the 2x2 table shown in Table 2:

176

$$P_{pos} = \frac{2a}{(a + b + c + d) + (a - d)}$$

177

$$P_{neg} = \frac{2d}{(a + b + c + d) - (a - d)}$$

178

$$P_{pa} = \frac{a}{a + b + c}$$

179

$$SE(P_{pos}) = \sqrt{\left\{ \left[\frac{2}{(1 + P_{pa})^2} \right]^2 \times \left[\frac{P_{pa}(1 - P_{pa})}{a + b + c} \right] \right\}}$$

180

$$P_{na} = \frac{d}{b + c + d}$$

181

$$SE(P_{neg}) = \sqrt{\left\{ \left[\frac{2}{(1 + P_{na})^2} \right]^2 \times \left[\frac{P_{na}(1 - P_{na})}{b + c + d} \right] \right\}}$$

182

183

184 For purposes of comparison, Cohen's kappa co-efficient (Kappa) and 95% CIs was calculated
185 using IBM SPSS Statistics 24 (Cohen, 1960).

186

187 In this study, inferences were drawn primarily from the values for P_{pos} and P_{neg} (as opposed to
188 Kappa). This is because P_{pos} and P_{neg} identify how the tests behave separately for infected and
189 non-infected animals, which is more in line with the goals of this investigation. Relying on
190 the value of Kappa alone in studies such as this is misleading, as Kappa is an omnibus index
191 which combines both positive and negative agreement (Cicchetti and Feinstein, 1990). Such
192 omnibus indices may have deceptive effects on the interpretation of results, as the
193 contribution of positive and negative agreement to the value of Kappa cannot be evaluated
194 separately, and the observational process will be obscured (Cicchetti and Feinstein, 1990). To
195 fully appraise results of studies on test agreement, examination of the P_{pos} and P_{neg}
196 individually should be carried out, as this may yield a more nuanced interpretation of the
197 results (Cicchetti and Feinstein, 1990).

198

199

200

201

202 **Results**

203

204 Three hundred and sixty-nine lungs out of the 1911 examined (19%) were selected due to the
205 presence of macroscopic lesions of any type on preliminary examination at the abattoir. As
206 outlined in Figure 2, 18 lungs were classed as positive for JSRV infection (based on the
207 presence of macroscopic lesions consistent with OPA) by ME. Twelve lungs had lesions
208 consistent with JSRV infection (based on the presence of histologic lesions consistent with
209 OPA) by HE. Thirty lungs were positive for JSRV by RT-PCR. These results are described in
210 greater detail elsewhere (Lee et al., 2017). In summary, six cases of JSRV infection were
211 diagnosed by RT-PCR in sheep with macroscopic OPA lesions, seven cases of JSRV
212 infection were diagnosed in sheep with histologic OPA lesions, four cases of JSRV infection
213 without histologic lesions were diagnosed, and five tumours with JSRV RT-PCR negative
214 status (i.e. non-OPA tumours) were detected. Only two sheep were confirmed to be infected
215 with JSRV that had OPA lesions detected on both ME and HE. Nineteen sheep were positive
216 for JSRV by RT-PCR that were negative on ME and HE.

217

218 Results for calculations of the measures of agreement are shown in Table 3. P_{pos} values
219 ranged from 0.13 to 0.38, whereas P_{neg} values ranged from 0.95-0.96. The highest P_{pos} was
220 obtained between ME-HE_{parallel} and RT-PCR (0.38). In general, Kappa values were low (0.12
221 to 0.33) with three values falling into the range of ‘slight agreement’ and two into the range
222 of ‘fair agreement’ (Kundel and Polansky, 2003). The highest Kappa value (0.33) was
223 obtained for agreement between ME-HE_{parallel} and RT-PCR, the same pair of tests for which
224 the highest P_{pos} was obtained.

225

226 **Discussion**

227

228 The aim of this study was to determine an optimal way of using ME and HE along with RT-
229 PCR in order to detect JSRV infection post-mortem in a group of sheep.

230

231 The P_{pos} between ME-HE_{parallel} and RT-PCR (0.38; 95% CI: 0.32 - 0.44) was the highest
232 obtained, indicating that this particular combination of tests yields the highest percentage of
233 true positives for JSRV. However, given that this value represents a relatively low level of
234 correlation with RT-PCR, RT-PCR is recommended to rule in or out the presence of JSRV
235 infection, although was still low. This approach increases the number of true JSRV-positive
236 cases diagnosed compared to using ME-HE series; (36% [11/30] of JSRV-positive animals
237 were diagnosed using the methods in parallel compared to 6% [2/30] using the methods in
238 series) or individually. If lungs were selected for RT-PCR based on ME alone, only 20%
239 (6/30) cases of JSRV infection would have been diagnosed. If lungs were selected based on
240 HE alone, only 23% (7/30) cases of JSRV infection (the seven sheep with OPA) would have
241 been diagnosed. In other words, if lungs are macroscopically positive for OPA and/or
242 histologically positive for OPA, RT-PCR is a useful adjunct tool to confirm if JSRV is
243 present and to detect false positives which would have resulted by using ME and/or HE
244 alone, without RT-PCR.

245 A consistently high P_{neg} was obtained for all combinations of tests (0.95 - 0.96), showing a
246 high agreement of negative status between tests. This indicates that when there is a negative
247 test result for ME, HE, ME-HE_{series}, or ME-HE_{parallel}, RT-PCR will almost always be
248 negative.

249

250 Therefore the recommendations based on these results are: 1) preselect lungs from the sheep
251 population of interest that have macroscopic lesions of any type for further macroscopic,
252 histopathologic and RT-PCR examination, 2) if a sample of sheep lung contains lesions
253 consistent with JSRV infection (based on the presence of OPA lesions on ME and/or HE)
254 RT-PCR should be performed to determine if JSRV involvement is present and 3) if a sample
255 of sheep lung does not contain lesions consistent with JSRV infection (based on the absence
256 of lesions of OPA on both ME and HE), a subsequent RT-PCR is unnecessary, as it is also
257 very likely to be negative. This guidance differs from the generally-accepted method of post-
258 mortem OPA (and hence JSRV infection) diagnosis in which ME followed by HE are usually
259 considered sufficient for both positive and negative OPA diagnosis (Scott et al., 2013), with
260 PCR on lung tissue only being used in equivocal cases in which other lesions (e.g.
261 bronchopneumonia) may obscure those due to OPA (Scott et al., 2013). In addition, the
262 definition of what constitutes an equivocal case is subjective. The approach outlined above is
263 most useful in detecting whether or not JSRV infection is present in a group of animals (e.g.
264 cohorts from the same flock) whose lungs are examined post-mortem as part of a flock health
265 investigation of respiratory disease, ill-thrift or other relevant problem.

266

267 This approach may seem somewhat contradictory, as 19 cases of JSRV infection were missed
268 (those that had no lesions of OPA on ME or HE). However if the goal of the investigation is
269 to ascertain if infection is or is not present in a flock, the approach outlined here is sufficient,
270 as it is not necessary to detect every case, and the cost of carrying out RT-PCR on all animals
271 examined is great. For instance, the cost of an RT-PCR test for JSRV as offered by the
272 Department of Agriculture Laboratory Service in Ireland is €10.10 (\$11.40 US dollars/£8.70
273 pounds sterling at the time of writing). Therefore, the cost of testing all sheep with any type
274 of gross lesions selected for further testing in this study (n = 369) would have been €3726.90,

275 compared to the €282.80 required to test all those with macroscopic or histologic lesions (n =
276 28). This constitutes a cost saving of 92%. Given the low prevalence of JSRV infection and
277 OPA in Ireland and the UK we anticipate that the number of lungs to be tested during flock
278 health surveys would not be excessive (Cousens et al., 2015; Lee et al., 2017).

279

280 We note parenthetically that Kappa values obtained for agreement between RT-PCR and the
281 other tests (0.1-0.33) were low, indicating poor agreement when corrected for chance (Cohen,
282 1960). However, as discussed previously, the single omnibus value of Kappa gives us no
283 indication of how to deal with positive versus negative results. Therefore, the Kappa-
284 coefficient serves little practical use in this study as it provides no help in indicating how to
285 use the diagnostic tests described, although its calculation emphasizes the limitations of this
286 commonly used measure of agreement.

287

288 A potential limitation of this study is the assumption of perfect sensitivity and specificity of
289 the RT-PCR for JSRV. It is assumed that current RT-PCR techniques detecting the unique
290 U3 region of the JSRV long terminal repeat approach 100% specificity (Bai et al., 1996). The
291 sensitivity of PCR using the same primers assessed *in vitro* suggests this assay can detect a
292 single molecule of template DNA in a background of 500ng of normal sheep genomic DNA
293 (Palmarini et al., 1996). As all previous studies have, to the authors' knowledge, invariably
294 found OPA-affected lung tissue to be positive by PCR or RT-PCR for JSRV (Bai et al., 1996;
295 Caporale et al., 2005; De Las Heras et al., 2005; Garcia-Goti et al., 2000; Gonzalez et al.,
296 2001; Kycko et al., 2008; Palmarini et al., 1996; Palmarini et al., 1999; Salvatori et al., 2004)
297 and as we are using the same primers and conditions, we consider the assumption regarding
298 sensitivity and specificity to be reasonable.

299 Our approach was developed using a population of clinically normal slaughtered sheep.
300 Therefore, the most useful application of this study may be in investigations aiming to detect
301 the presence of JSRV infection within an individual population or flock. This is different to
302 the context of post-mortem examination on an individual animal where more information is
303 usually available (e.g. clinical and flock history and full examination of the animal carcass).
304 In this case, the use of RT-PCR may be at the pathologist's discretion and may take into
305 account other factors, such as the value of the animal or the flock. In contrast, in a prevalence
306 survey for JSRV infection. it is important in the context of study design that all animals are
307 tested identically, so all (or none) should have PCR carried out.

308

309 This study has value in that it provides evidence-based information regarding the diagnosis of
310 JSRV infection. Traditionally, pathology relies on empirical knowledge to make diagnoses
311 (Wick and Marchevsky, 2011). However, a more evidence-based approach also has merit
312 (Fleming, 1996). Evidence-based medicine “depends on the use of logic and appropriate
313 statistical methods to identify data-based concepts and procedures and separate them from
314 observational ones” (Wick and Marchevsky, 2011). In human medicine many studies have
315 been undertaken to assess the reliability and consistency of anatomical pathological
316 diagnoses, both histologic and macroscopic (Fleming, 1996). We suggest a similar approach
317 be adopted in veterinary medicine as described in the present study.

318

319 **Conclusion**

320

321 We have shown that the use of ME and HE in parallel is optimal in terms of reaching a
322 diagnosis of JSRV infection at post-mortem. If a positive result on either or both of these

323 tests is obtained, a confirmatory RT-PCR for JSRV should be carried out. If a negative result
324 on both tests is obtained, the sample is likely to yield a negative RT-PCR result and therefore
325 testing is unlikely to aid the diagnostic process in the vast majority of cases.

326

327 Given that the prevalence of JSRV is generally low in the sheep population, we predict that
328 most animals will be negative for both macroscopic and histologic lesions of OPA and RT-
329 PCR testing will not be required. However, RT-PCR, when applied based on the presence of
330 OPA lesions on ME and/or HE, is a useful adjunct to diagnosing JSRV infection in sheep.

331

332

333

334

335

336

337

338

339

340

341

342

343

344 **References**

345

346 Bai, J., Zhu, R.Y., Stedman, K., Cousens, C., Carlson, J., Sharp, J.M., DeMartini, J.C., 1996.
347 Unique long terminal repeat U3 sequences distinguish exogenous jaagsiekte sheep
348 retroviruses associated with ovine pulmonary carcinoma from endogenous loci in the
349 sheep genome. *J. Virol.* 70, 3159-3168.

350

351 Caporale, M., Centorame, P., Giovannini, A., Sacchini, F., Di Ventura, M., De las Heras, M.,
352 Palmarini, M., 2005. Infection of lung epithelial cells and induction of pulmonary
353 adenocarcinoma is not the most common outcome of naturally occurring JSRV
354 infection during the commercial lifespan of sheep. *Virology.* 338, 144-153.
355 <https://doi.org/10.1016/j.virol.2005.05.018>.

356

357 Caswell, J.L., Williams, K.J., 2016. Respiratory System, in: Maxie, M.G. (Ed.), Jubb,
358 Kennedy and Palmer's Pathology of Domestic Animals, sixth ed. Elsevier, St. Louis,
359 pp. 465-591.

360

361 Cicchetti, D.V., Feinstein, A.R., 1990. High agreement but low kappa: II. Resolving the
362 paradoxes. *J. Clin. Epidemiol.* 43, 551-558. [https://doi.org/10.1016/0895-](https://doi.org/10.1016/0895-4356(90)90159-M)
363 [4356\(90\)90159-M](https://doi.org/10.1016/0895-4356(90)90159-M).

364

365 Cohen, J., 1960. A coefficient of agreement for nominal scales. *Educ. Psychol. Meas.* 20, 37-
366 46. <https://doi.org/10.1177/001316446002000104>.

367

368 Cousens, C., Gibson, L., Finlayson, J., Pritchard, I., Dagleish, M.P., 2015. Prevalence of
369 ovine pulmonary adenocarcinoma (Jaagsiekte) in a UK slaughterhouse sheep study.
370 Vet. Rec. 176, 413-413. <http://dx.doi.org/10.1136/vr.102880>.
371

372 Dalefield, R.R., Alley, M.R., 1988. An ovine pulmonary tumour of alveolar epithelial Type II
373 cells. New Zeal. Vet. J. 36, 25-27.
374

375 De las Heras, M., Ortín, A., Salvatori, D., de Villareal, M.P., Cousens, C., Ferrer, L.M.,
376 Cebrián, L.M., de Jalón, J.A.G., Gonzalez, L., Sharp, J.M., 2005. A PCR technique
377 for the detection of Jaagsiekte sheep retrovirus in the blood suitable for the screening
378 of ovine pulmonary adenocarcinoma in field conditions. Res. Vet. Sci. 79, 259-264.
379 <https://doi.org/10.1016/j.rvsc.2005.02.003>.
380

381 Feinstein A.R., Cicchetti, D.V., 1990. High agreement but low kappa: I. The problems of two
382 paradoxes. J. Clin. Epidemiol. 43, 543-549. [https://doi.org/10.1016/0895-](https://doi.org/10.1016/0895-4356(90)90158-L)
383 [4356\(90\)90158-L](https://doi.org/10.1016/0895-4356(90)90158-L).
384

385 Fleming, K.A., 1996. Evidence-based pathology. J. Pathol. 179, 127-128.
386 [https://doi.org/10.1002/\(SICI\)1096-9896\(199606\)179:2<127::AID-](https://doi.org/10.1002/(SICI)1096-9896(199606)179:2<127::AID-PATH519>3.0.CO;2-Z)
387 [PATH519>3.0.CO;2-Z](https://doi.org/10.1002/(SICI)1096-9896(199606)179:2<127::AID-PATH519>3.0.CO;2-Z).
388

389 Garcia-Goti, M., Gonzalez, L, Cousens, C., Cortabarría, N., Extramiana, A.B., Minguíjon, E.,
390 Ortin, A., De las Heras, M., Sharp, J.M., 2000. Sheep pulmonary adenomatosis:
391 characterization of two pathological forms associated with jaagsiekte retrovirus. J.
392 Comp. Pathol. 122, 55-65. <https://doi.org/10.1053/jcpa.1999.0344>.

393

394 Gonzalez, L., Garcia-Goti, M., Cousens, C., Dewar, P., Cortabarría, N., Extramiana, A.B.,
395 Ortín, A., De Las Heras, M., Sharp, J.M., 2001. Jaagsiekte sheep retrovirus can be
396 detected in the peripheral blood during the pre-clinical period of sheep pulmonary
397 adenomatosis. *J. Gen. Virol.* 82, 1355-1358. [https://doi: 10.1099/0022-1317-82-6-](https://doi: 10.1099/0022-1317-82-6-1355)
398 1355.

399

400 Grego, E., De Meneghi, D., Álvarez, V., Benito, A.A., Minguijón, E., Ortín, A., Mattoni, M.,
401 Moreno, B., De Villarreal, M.P., Alberti, A., Capucchio, M.T., 2008. Colostrum and
402 milk can transmit jaagsiekte retrovirus to lambs. *Vet. Microbiol.* 130, 247-257.
403 <https://doi.org/10.1016/j.vetmic.2008.01.011>.

404

405 Griffiths, D.J., Martineau, H.M., Cousens, C., 2010. Pathology and pathogenesis of ovine
406 pulmonary adenocarcinoma. *J. Comp. Pathol.* 142, 260-283.
407 <https://doi.org/10.1016/j.jcpa.2009.12.013>.

408

409 Hooper, P.T, Ellard, K.A. A pulmonary adenoma in an Australian sheep, 1995. *Aust. Vet. J.*
410 72, 477-477.

411

412 Kundel, H.L., Polansky, M., 2003. Measurement of observer agreement. *Radiology.* 228,
413 303-308. <https://doi.org/10.1148/radiol.2282011860>.

414

415 Kycko, A., Jasik, A., Reichert, M., 2008. Detection of jaagsiekte sheep retrovirus in
416 respiratory tract fluid and lung tissue of experimentally infected lambs. *B. Vet. I.*
417 *Pulawy.* 52, 9-13.

418

419 Lee, A.M., Wolfe, A., Cassidy, J.P., Messam, L.L.M., Moriarty, J.P., O'Neill, R., Fahy, C.,
420 Connaghan, E., Cousens, C., Dagleish, M.P., McElroy, M.C., 2017. First confirmation
421 by PCR of Jaagsiekte sheep retrovirus in Ireland and prevalence of ovine pulmonary
422 adenocarcinoma in adult sheep at slaughter. *Irish Vet. J.* 70, 33.
423 <https://doi.org/10.1186/s13620-017-0111-z>.

424

425 Oehlert, G.W., 1992. A note on the delta method. *Am. Stat.* 46, 27-29.

426

427 Palmarini, M., Holland, M. J., Cousens, C., Dalziel, R. G., Sharp, J. M., 1996. Jaagsiekte
428 retrovirus establishes a disseminated infection of the lymphoid tissues of sheep
429 affected by pulmonary adenomatosis. *J. Gen. Virol.* 77, 2991-2998. [https://doi:](https://doi:10.1099/0022-1317-77-12-2991)
430 [10.1099/0022-1317-77-12-2991](https://doi:10.1099/0022-1317-77-12-2991).

431

432 Palmarini, M., Sharp, J.M., De Las Heras, M., Fan, H., 1999. Jaagsiekte sheep retrovirus is
433 necessary and sufficient to induce a contagious lung cancer in sheep. *J. Virol.* 73,
434 6964-6972.

435

436 Salvatori, D., Gonzalez, L., Dewar, P., Cousens, C., de las Heras, M., Dalziel, R.G., Sharp,
437 J.M., 2004. Successful induction of ovine pulmonary adenocarcinoma in lambs of
438 different ages and detection of viraemia during the preclinical period. *J. Gen. Virol.*
439 85, 3319-3324. [https://doi: 10.1099/vir.0.80333-0](https://doi:10.1099/vir.0.80333-0).

440

441 Scott, P., Griffiths, D., Cousens, C., 2013. Diagnosis and control of ovine pulmonary
442 adenocarcinoma (Jaagsiekte). In Practice. 35, 382-397.
443 <https://dx.doi.org/10.1136/inp.f4427>.

444

445 Wick, M.R., Marchevsky, A.M., 2011. Evidence-based principles in pathology: existing
446 problem areas and the development of “quality” practice patterns. Arch. Pathol. Lab.
447 Med. 135, 1398-1404. <https://doi.org/10.5858/arpa.2011-0181-SA>.

448

449

450

451

452

453

454

455

456

457

458

459

460

461

462 **Tables**

463

Table 1. Agreement between RT-PCR and a) histologic examination, b) macroscopic examination, c) macroscopic examination and histologic examination in series, and d) macroscopic and histologic examination in parallel during ovine lung tissue diagnosis of Ovine Pulmonary Adenocarcinoma in Ireland, 2015.

Test		RT-PCR		
		Positive	Negative	Total
a. Histologic examination	Positive	7	5	12
	Negative	23	334	357
	Total	30	339	369
b. Macroscopic examination	Positive	6	12	18
	Negative	24	327	351
	Total	30	339	369
c. Macroscopic examination and histologic examination in series	Positive	2	0	2
	Negative	28	339	367
	Total	30	339	369
d. Macroscopic and histologic examination in parallel	Positive	11	17	28
	Negative	19	322	341
	Total	30	339	369

464

465

466

Table 2: Two-by-two table as used for the calculation of positive and negative agreement.

		Test 2		
		+	-	
Test 1	+	a	b	a + b
	-	c	d	c + d
		a + c	b + d	a + b + c + d

467

468

469

470

471

472

473

474

475

476

477

478

479

480

481

482

483

Table 3. Results for calculations of measures of agreement. P_{pos} , Positive agreement; P_{neg} , Negative agreement; κ , Kappa; 95% CI, 95% confidence interval.

	P_{pos}	P_{neg}	κ
	95% CI	95% CI	95% CI
Histologic examination and RT-PCR	0.33 (0.27-0.39)	0.96 (0.95-0.97)	0.30 (0.12-0.49)
Macroscopic examination and RT-PCR	0.25 (0.21-0.29)	0.95 (0.93-0.96)	0.20 (0.04-0.38)
Macroscopic and histologic examinations in series and RT-PCR	0.13 (0.11-0.14)	0.96 (0.95-0.97)	0.12 (0.00-0.27)
Macroscopic and histologic examinations in parallel and RT-PCR	0.38 (0.32-0.44)	0.95 (0.93-0.96)	0.33 (0.14-0.49)

484

485

486

487

488 **Figure legends**

489

490 Figure 1: Tests interpreted in series and in parallel. A) Two diagnostic tests used in series: A
491 positive result on both tests must be obtained for the overall result to be considered positive.
492 A negative result on one or both tests is considered to be a negative result. B) Two diagnostic
493 tests used in parallel: A positive result on one or both tests must be obtained for the overall
494 result to be considered positive. A negative result on both tests is considered to be a negative
495 result.

496

497 Figure 2: Venn diagram showing the process used for selection of lungs as well as
498 distribution of the results of the macroscopic and histological examination for lesions
499 consistent with Ovine Pulmonary Adenocarcinoma and reverse-transcriptase polymerase
500 chain reaction (RT-PCR) for Jaagsiekte Sheep Retrovirus in 369 sheep in Ireland (September-
501 December 2015). HE: Histologic examination; HSO: Histologically-suspect OPA; ME:
502 Macroscopic examination; MSO: Macroscopic-suspect OPA.

503

504

505

506

507

508

509

510 *Acknowledgements*

511

512 The authors would like to thank Eddie Mooney, Brian Cloak and Alex Fawcett for technical
513 assistance; Seamus Fagan, and Colm Brady for assisting with lung examination, Denis
514 Carroll, Maurice O’Flaherty, Nikolay Semerdzhiev, and staff at Kildare Chilling Co. for
515 facilitating lung collection.

516

517 *Declarations of interest*

518 None

519

520 *Funding*

521 This research did not receive any specific grant from funding agencies in the public,
522 commercial, or not-for-profit sectors.

523

524

525

526

527

A.

Test 1	Test 2
+	+
+	-
-	+
-	-

Positive result: Test in series

Negative result: Test in series

B.

Test 1	Test 2
+	+
+	-
-	+
-	-

Positive result: Test in parallel

Negative result: Test in parallel

1

Lung examination at abattoir
(n = 1911 lungs examined)

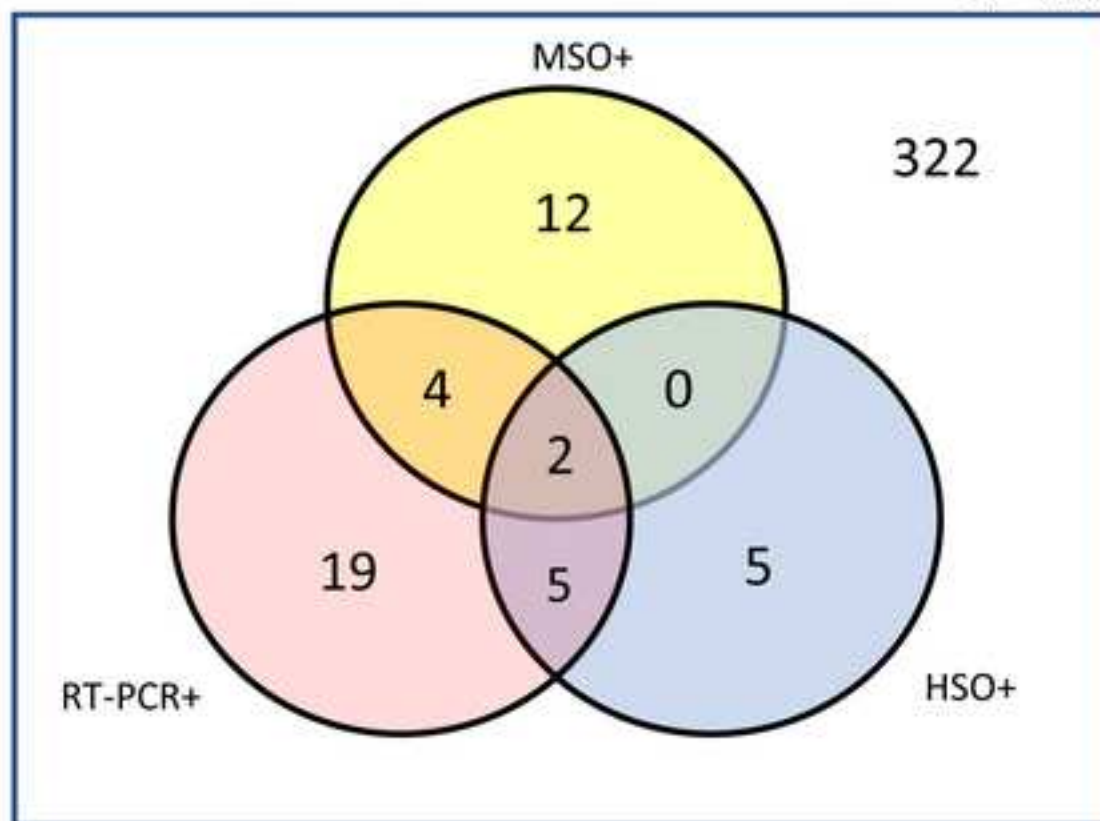


Lungs with any lesion type selected for further examination
(n = 369 lungs selected)



ME and HE (for lesions of OPA) and RT-PCR
(for JSRV) carried out (results below)

N = 369



An approach to diagnosis of Jaagsiekte sheep retrovirus infection in sheep based on assessment of agreement between macroscopic examination, histopathologic examination and reverse-transcriptase polymerase chain reaction.

Declarations of interest: None

Data Statement

[Click here to download Data Statement: data_JSRR_may19.docx](#)