



Title	Is Grannum Grading of the Placenta Reproducible?
Authors(s)	Moran, Mary, Ryan, John, Brennan, Patrick, Higgins, Mary, McAuliffe, Fionnuala M.
Publication date	2009-03-12
Publication information	Moran, Mary, John Ryan, Patrick Brennan, Mary Higgins, and Fionnuala M. McAuliffe. "Is Grannum Grading of the Placenta Reproducible?" SPIE, March 12, 2009. https://doi.org/10.1117/12.810993 .
Publisher	SPIE
Item record/more information	http://hdl.handle.net/10197/7660
Publisher's version (DOI)	10.1117/12.810993

Downloaded 2026-05-01 23:34:25

The UCD community has made this article openly available. Please share how this access benefits you. Your story matters! (@ucd_oa)



© Some rights reserved. For more information

Is Grannum Grading of the Placenta Reproducible?

Mary Moran^{*a}, John Ryan^a, Patrick C Brennan^a, Mary Higgins^{ab}, Fionnuala M McAuliffe^{ab}

^aSchool of Medicine and Medical Science, University College Dublin, Dublin 4, Ireland;

^bNational Maternity Hospital, Holles St, Dublin 2, Ireland.

ABSTRACT

Current ultrasound assessment of placental calcification relies on Grannum grading. The aim of this study was to assess if this method is reproducible by measuring inter- and intra-observer variation in grading placental images, under strictly controlled viewing conditions. Thirty placental images were acquired and digitally saved. Five experienced sonographers independently graded the images on two separate occasions. In order to eliminate any technological factors which could affect data reliability and consistency all observers reviewed images at the same time. To optimise viewing conditions ambient lighting was maintained between 25-40 lux, with monitors calibrated to the GSDF standard to ensure consistent brightness and contrast. Kappa (κ) analysis of the grades assigned was used to measure inter- and intra-observer reliability. Intra-observer agreement had a moderate mean κ -value of 0.55, with individual comparisons ranging from 0.30 to 0.86. Two images saved from the same patient, during the same scan, were each graded as I, II and III by the same observer. A mean κ -value of 0.30 (range from 0.13 to 0.55) indicated fair inter-observer agreement over the two occasions and only one image was graded consistently the same by all five observers. The study findings confirmed the lack of reproducibility associated with Grannum grading of the placenta despite optimal viewing conditions and highlight the need for new methods of assessing placental health in order to improve neonatal outcomes. Alternative methods for quantifying placental calcification such as a software based technique and 3D ultrasound assessment need to be explored.

Keywords: placental health, ultrasound assessment, observer variation

1. INTRODUCTION

The placenta is the most vital support organ for the developing fetus. Antenatal ultrasound assessment of placental morphology plays an important role in evaluating fetal health, revealing abnormalities such as infarcts and calcification. Currently ultrasound assessment of placental calcification relies on Grannum grading. This involves a subjective observation of the placenta and depending on the presence and location of the calcifications a grade of 0, I, II or III is given, the higher grade describing a higher degree of calcification¹. A certain degree of placental calcification is normal as the fetus approaches term, however accelerated placental maturation is associated with pregnancy induced hypertension, fetal growth restriction, and fetal distress in labour, all factors which contribute to an increased risk of morbidity and mortality^{2,3,4}. For this reason reporting of placental grading when performing an ultrasound examination during the third trimester is recommended³. Although first reported on 30 years ago placental grading remains the only recognised method of assessing placental calcification and is still a widely used tool. A recent study by McKenna et al⁵ found that a mother with a grade III placenta at 36 weeks' gestation was almost five times more likely to develop preeclampsia later in pregnancy and three times more likely to deliver a baby with a birth weight less than the tenth centile.

*moran.mary@ucd.ie; phone +353 1 7166543; fax +353 1 7166547

Using Grannum grading as a method of assessing placental health, however, may in part contribute to the lack of progress in identifying a high risk fetus in a low risk population. Studies have suggested this method lacks objectivity, precision and reproducibility⁶. However as there is no mention of controlling viewing conditions in previous studies variations found could have been for technological as much as observer factors. Optimum ambient lighting conditions and consistent presentation of digital ultrasound images are essential for both soft- and hard-copy for visualisation of normal anatomy and subtle pathologies^{7,8}. The aim of this study was to evaluate observer performance and to assess if inter- and intra-observer variability will be improved if placental grading is performed under strictly controlled viewing conditions. This is a pilot study which is part of a larger study investigating alternative methods of assessing placental function such as computerised assessment.

2. METHODOLOGY

This is a prospective comparative study. With institutional ethical approval and maternal written consent three hundred digital images of the placenta were stored from patients, who attended the fetal assessment unit at the National Maternity hospital, Dublin, between July and November 2007. For this pilot study thirty images were chosen which the author deemed to best represent the range of grades described by Grannum et al¹. Also two images from the same patient, saved during the one scan, were included in the thirty. Two experienced fetal medicine consultants and three full-time midwife sonographers independently graded the images, on two occasions. A number of controls were put in place to ensure that the observer was the only variable for this study. The five observers reviewed the images at the same time in the Diagnostic Imaging Observer Laboratory, School of Medicine and Medical Science, UCD. Prior to both image review sessions, the grading criteria were defined using the following descriptors⁹:

- Grade 0: The placental tissue and the basal plate are homogenous without the presence of linear highly reflective foci. The chorionic plate is smooth and well defined
- Grade I: The placental tissue contains a few linear highly reflective areas parallel to the basal plate, which remains unchanged. The chorionic plate presents subtle undulations.
- Grade II: The placental tissue contains randomly dispersed echoes and is divided by comma-like reflective structures continuous with the chorionic plate. The marked indentations of the chorionic plate do not reach the basal plate, which is well defined by small linear highly reflective areas.
- Grade III: The placental tissue is divided into compartments containing central echo-free areas. The chorionic plate indentations reach the basal plate, which contains almost confluent, very highly reflective areas.

Individual monitors were allocated to each observer. All monitors were calibrated to the GSDF (greyscale standard display function) standard to ensure equivalent brightness and contrast^{7,10}. The room (ambient) lighting was adjusted to make certain of a reading on all monitors of between 25 and 40 lux which ensures maximum image contrast, necessary for diagnostic accuracy^{11,12}. These controls guaranteed consistent observer perception of images for all five monitors, over both occasions. The observers sat apart and viewed the images in silence in order not to influence each other's decisions. They were asked to allocate a grade of 0, I, II or III to each image. They were then asked to review the same images one week later, with the images presented in a different order. Viewing conditions were identical to the first session, with each observer viewing the images on the same monitor as on the first occasion.

2.1 Statistical analysis

For each of the two viewing sessions statistical analysis was performed to compare, between each observer, the variability of the grades assigned. Individual observer comparisons of grades allocated on the two occasions were also evaluated. The degree of inter- and intra-observer agreement was compared using Kappa (κ) analysis, which is a statistical measure of inter-rater reliability. A value of 0.20 or less indicates poor agreement, between 0.21 and 0.40 fair agreement, moderate between 0.41 and 0.60, good between 0.61 and 0.80 and values of 0.81 and above indicate excellent agreement¹³.

3. RESULTS

Overall agreement between observers was fair, with a mean κ value of 0.30 with a range of 0.13 to 0.55

3.1 Inter-observer variation – First image assessment

Results from the first image review session demonstrate fair agreement between observers: with a mean κ value of 0.31 (range 0.20 to 0.55). Eight out of ten of the observer groupings showed fair agreement, and there was moderate agreement between two of the observer groupings only, κ values of 0.42 (observer A and E) and 0.55 (observers C and D). The κ values for inter-observer variation for the first image review session are represented in Figure 1.

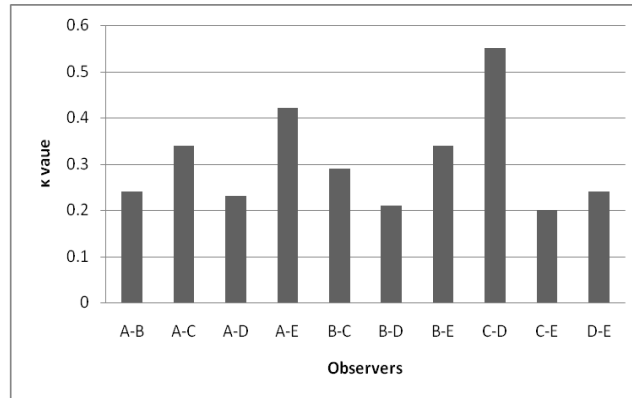


Fig. 1. Inter-observer variation of placental grading (1st review of images). Letters A-E refer to individual observers.

3.2 Inter-observer variation – Second image assessment

Figure 2 represents inter-observer variation at the second image review session. There was very little difference in the overall inter-observer variability at the second image review session. The mean κ value was 0.30 (fair agreement), with values ranging from 0.13 to 0.55. Two of the observer groupings had poor agreement (κ values 0.13 and 0.17), with only one observer group (B and D) showing moderate agreement (κ value 0.55). Some interesting inter-assessment variations were observed. At the first session there was only fair agreement between observers B and D (κ value 0.21), but this was good in the second viewing (κ value 0.55). In contrast to this there was a decrease in agreement at the second session for observers A and E, and C and D. Both groups had κ values indicating moderate agreement at the first session, however agreement was only poor between observers A and E, and fair between observers C and D at the second session.

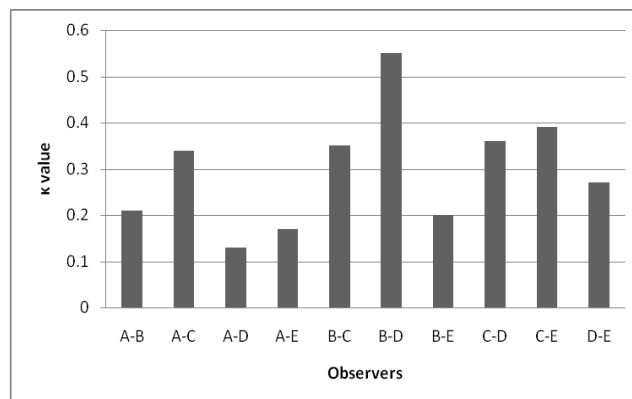


Fig. 2. Inter-observer variation of placental grading (2nd review of images). Letters A-E refer to individual observers.

Only one image was graded consistently the same (grade III) by all five observers at both image review sessions. Seven out of the 30 images were each given grades of I, II and III across both sessions. Two of these images are shown in Figure 3.

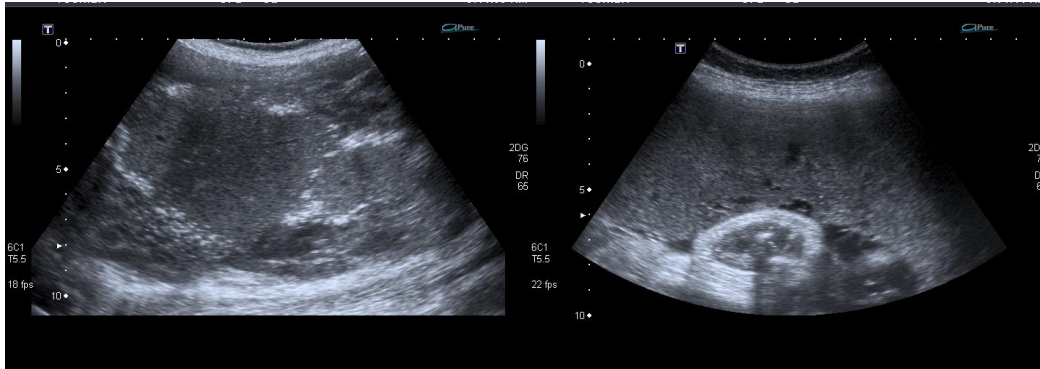


Fig. 3. Images assigned grades I to III by different observers

3.3 Intra-observer variation

Intra-observer agreement (represented in Figure 4) had a moderate mean κ -value of 0.55, with individual comparisons ranging from 0.30 to 0.86. There was excellent agreement of placental grading between the two image review sessions for one observer only (κ value 0.86). One observer had good agreement (κ value 0.76) and one moderate agreement (κ value 0.47). Two of the five observers had only fair agreement, with κ values of 0.3 and 0.39. One of the latter group was a fetal medicine specialist and the other one a midwife sonographer with four years obstetric scanning experience. There was generally only one grade difference between observations, however there were two images that had a difference of two grade points between observations. These are the two images depicted in Figure 3 which were also assigned grades I, II and III across observers.

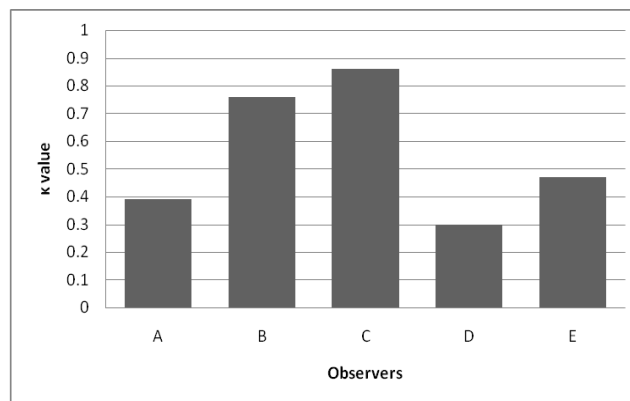


Fig. 4. Intra-observer variation of placental grading. Letters A-E refer to individual observers.

The two images saved from the same patient, during the same scan, were each graded as I, II and III by the same observer (Figure 5). The observer in question was a highly experienced fetal medicine specialist.

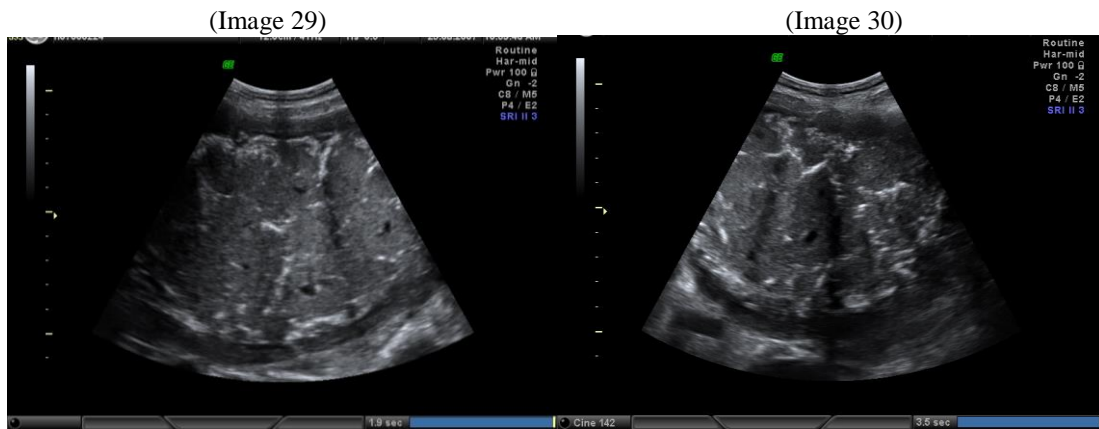

Fig. 5. Two images of the same placenta graded I, II and III by the same observer

4. DISCUSSION

This is the first study undertaken assessing inter- and intra-observer variation of placental grading, where the viewing conditions were strictly controlled, in order to eliminate any technological factors which could adversely affect the reliability of the results. Despite this there was a low level of agreement between observers in assessing placental calcification which highlights the subjectivity of Grannum grading. This occurred even though every effort was made to ensure consistency both in terms of agreed consensus on the classifications to be used for Grannum grading[8], and the strictly controlled viewing conditions that were employed. These strict controls guaranteed that the only variable in this study was the observer.

All five observers were highly trained. However at the first image review session inter-observer agreement was generally only fair and indeed at the second review of the images there was poor agreement between observer A and observers D and E. Twenty three percent of the images were each given grades of I, II and III and only one image was graded the same by all five observers. The results also show two of the observer groupings to have a poorer level of agreement at the second session, which indicates that re-enforcing the grading classifications for all observers only one week following the first session did not lead to a better level of agreement. Intra-observer agreement was better, ranging from excellent to fair. It is interesting that one of the observers who only had fair intra-observer agreement was a fetal medicine specialist with many years experience, suggesting the level of expertise of the observers did not seem to be an important factor.

One of the observers remarked that it was difficult to report on still images, particularly on some of the images in relation to distinguishing the basal plate from the chorionic plate. Any difficulties in distinguishing the different placental layers, however, should have been encountered to the same degree by all five observers. Also it must be noted that in some centres ultrasound images are not reported on by the sonographer performing the live scan, but are in fact reported on at a later stage, with assessment of still images by a fetal medicine specialist or radiologist. The comments of the observer in this study suggest where placental images are not graded in practice by the person performing the scan it would be good practice to record an image sequence for subsequent reporting.

Grannum grading is subjective both in terms of the correct image of the placenta that should be acquired and how that image is assessed for calcification. The results of this pilot study have raised many questions and set the stage for further research in this area. At this stage it is evident that a protocol must be developed to ensure that the correct parameters are used for optimal image acquisition and that a more objective method of assessing placental function is required. One possible option is digital analysis. Initial work on a new 2D ultrasound imaging software tool developed in the School of Medicine and Medical Sciences, University College Dublin has shown promising results¹⁴. The possibility of using 3/4D ultrasound to assess the placenta is another option which is being explored. Further research in this area is vital if progress is to be made in utilising the placenta as part of the assessment of fetal health.

5. CONCLUSION

This study confirms the view that ultrasound assessment of placental calcification by Grannum grading has poor reproducibility and highlights the need for new methods of assessing placental health. This is vital if progress is to be made in identifying the high-risk fetus in the low-risk population, which in turn will lead to improved neonatal outcomes. Alternative methods for improving the quality and diagnostic accuracy of placental imaging need to be explored

REFERENCES

- [1] Grannum, P.A., Berkowitz, R.L. Hobbins, J.C., "The ultrasonic changes in the maturing placenta and their relation to fetal pulmonary maturity," *Am J Obstet Gynecol*, 133(8), 915-922 (1979).
- [2] Veena, A., Sapna J., "Placental Grade and its Correlation with Foetal outcome," *J Obstet Gynecol Ind*, 50, 59-62 (2000).
- [3] Proud, J., Grant, A.M., "Third trimester placental grading by ultrasonography as a test of fetal wellbeing," *British Medical Journal*, 294, 1641-1644 (1987).
- [4] Hills, D., Irwin, G., Tuck, S., Baim R. "Distribution of Placental Grade in High-Risk Gravida," *AJR*, 143, 1011-1013 (1984).
- [5] McKenna, D., Tharmaratnam, S., Mahsud, S., Dornan, J., "Ultrasonic evidence of placental calcification at 36 weeks' gestation: maternal and fetal outcomes," *Acta Obstet Gynecol Scand*, 84, 7-10 (2005)
- [6] Sau, A., Seed, P., Langford K., "Intraobserver and interobserver variation in the sonographic grading of placental maturity," *Ultrasound Obstet Gynecol*, 23, 374-377 (2004).
- [7] Fetterly, K.A., Blume, H.R., Flynn, M.J., Ehsan, S., "Introduction to Greyscale Calibration and Related Aspects of Medical Imaging Grade Liquid Crystal Displays," *Proc. SPIE 5748*, 193-207 (2008).
- [8] Wade, C., Brennan, P.C., McEntee, M.F., "An Assessment of the Performance and Quality Control Procedures of PACS Workstation Monitors used in Irish Radiology Departments," *Proc. SPIE 5748*, 244-245 (2005).
- [9] Jauniaux E. "The Placenta". In: Dewbury, K., Meire, H., Cosgrove, D., Farrant, P., eds. [Ultrasound in Obstetrics and Gynaecology], Churchill Livingstone, London, 529-555 (2001).
- [10] Goo, J.M., Choi, J.Y., Im, J.G., Lee, H.J., Chung, M.J., Han, D., et al. "Effect of Monitor Luminance and Ambient Light on Observer Performance in Soft-Copy Reading of Digital Chest Radiographs," *Radiology*, 232(3), 762-766 (2004).
- [11] Brennan, P.C., McEntee, M., Evanoff, M., Phillips, P., O'Connor, W.T., Manning, D.J. "Ambient Lighting: Effect of Illumination on Soft-Copy Viewing of Radiographs of the Wrist," *AJR*, 188, W177-W180 (2007).
- [12] Chakrabarti, K., Kaczmarek, R.V., Thomas, J.A., Romanyukha, A., "Effect of Room Illuminance on Monitor Black Level Luminance and Monitor Calibration," *Journal of Digital Imaging*, 16(4), 350-355 (2003).
- [13] Landis, J., Koch, G., "The measurement of observer agreement for categorical data," *Biometrics*, 33, 159-174 (1977).
- [14] Ryan, J., McAuliffe, F., Higgins, M., Stanton, M., Brennan, P., "A novel software-based technique for quantifying placental calcifications and infarctions from ultrasound," *Proc. SPIE 6290*, 1-8 (2008).

Cite as: Proc. SPIE **7263**, 72631W (2009)

Mar 12, 2009