



<b>Title</b>	Atypical Alstrom syndrome with novel ALMS1 mutations precluded by current diagnostic criteria
<b>Authors(s)</b>	Casey, Jillian, McGettigan, Paul A., Brosnahan, Donal, et al.
<b>Publication date</b>	2014-02
<b>Publication information</b>	Casey, Jillian, Paul A. McGettigan, Donal Brosnahan, and et al. "Atypical Alstrom Syndrome with Novel ALMS1 Mutations Precluded by Current Diagnostic Criteria." Elsevier, February 2014. <a href="https://doi.org/10.1016/j.ejmg.2014.01.007">https://doi.org/10.1016/j.ejmg.2014.01.007</a> .
<b>Publisher</b>	Elsevier
<b>Item record/more information</b>	<a href="http://hdl.handle.net/10197/5689">http://hdl.handle.net/10197/5689</a>
<b>Publisher's statement</b>	This is the author's version of a work that was accepted for publication in Journal of Medical Genetics. Changes resulting from the publishing process, such as peer review, editing, corrections, structural formatting, and other quality control mechanisms may not be reflected in this document. Changes may have been made to this work since it was submitted for publication. A definitive version was subsequently published in Journal of Medical Genetics (VOL 57, ISSUE 2-3, (2014)) DOI:10.1016/j.ejmg.2014.01.007
<b>Publisher's version (DOI)</b>	<a href="https://doi.org/10.1016/j.ejmg.2014.01.007">10.1016/j.ejmg.2014.01.007</a>

Downloaded 2026-05-02 00:27:55

The UCD community has made this article openly available. Please share how this access benefits you. Your story matters! (@ucd\_oa)



© Some rights reserved. For more information

## **Atypical Alstrom syndrome with novel ALMS1 mutations precluded by current diagnostic criteria**

Jillian Casey<sup>a,b</sup>, Paul McGettigan<sup>b,c</sup>, Donal Brosnahan<sup>d</sup>, Emma Curtis<sup>e</sup>, Eileen Treacy<sup>f</sup>, Sean Ennis<sup>b,g</sup>, Sally Ann Lynch<sup>b,g,h</sup>

<sup>a</sup> National Children's Research Centre, Our Lady's Children's Hospital, Crumlin, Dublin 12, Ireland

<sup>b</sup> Academic Centre on Rare Diseases, School of Medicine and Medical Science, University College Dublin, Belfield, Dublin 4, Ireland

<sup>c</sup> UCD School of Agriculture, Food Science and Veterinary Medicine, University College Dublin, Dublin 4, Ireland

<sup>d</sup> Ophthalmology Department, Our Lady's Children's Hospital, Crumlin, Dublin 12, Ireland

<sup>e</sup> Community Child Health/Neurology, The Adelaide and Meath Hospital, Tallaght, Dublin 24, Ireland

<sup>f</sup> National Centre for Inherited Metabolic Disorders, Temple Street Children's University Hospital, Dublin 1, Ireland

<sup>g</sup> National Centre for Medical Genetics, Our Lady's Children's Hospital, Crumlin, Dublin 12, Ireland

<sup>h</sup> Genetics Department, Children's University Hospital, Temple Street, Dublin 1, Ireland

**Corresponding author:** Dr Sally Ann Lynch, National Centre for Medical Genetics, Our Lady's Children's Hospital, Crumlin, Dublin 12, Ireland. Tel.: +353 1 4096110; Fax: +353 1 4560953; E-mail: [sallyann.lynch@olchc.ie](mailto:sallyann.lynch@olchc.ie)

**Running Title:** Novel ALMS1 mutations in atypical Alstroms

## **Abstract**

We report on clinical and genetic studies in a non-consanguineous Irish sib-pair with infantile dilated cardiomyopathy and retinopathy. A diagnosis of Alström Syndrome (AS) was considered and diagnostic testing pursued. The Alströms gene (*ALMS1*) is very large (23 exons) and diagnostic testing of mutational hotspots (exon 6, 8 and 10) was negative. Furthermore the siblings were tall and did not have the typical phenotype of nystagmus, photophobia, obesity or hearing loss and so the AS diagnosis was removed. We then sought to identify the causative gene in this family using whole exome sequencing. Unexpectedly, the exome analysis identified novel compound heterozygous *ALMS1* mutations in exon 5 (c.777delT;p.D260fs\*26) and exon 20 (c.12145\_12146insC;p.S4049fs\*36) that segregated with the phenotype. Although the siblings show some clinical overlap with AS, their phenotype is not classical. It is plausible that their atypical presentation may be due to the location of the *ALMS1* mutations outside the usual mutational hotspots. Our findings show how atypical cases of AS may be missed under the current diagnostic guidelines and support consideration of complete *ALMS1* sequencing in children with two or more features, even if all of the core clinical features of AS are not present.

**Key words:** Alström Syndrome; *ALMS1*; autosomal recessive dilated cardiomyopathy; cone-rod dystrophy; exome; genotype-phenotype correlations

## 1. Introduction

We report on a pair of Irish siblings (male and female) with dilated cardiomyopathy (DCM) and cone-rod dystrophy born to non-consanguineous, phenotypically normal parents (Fig. 1). Abnormalities of the heart and eye are part of the spectrum of clinical features observed in Alström Syndrome (AS) (OMIM 203800). Nearly all AS patients (98%) develop nystagmus and photophobia as well as truncal obesity (~100%) in the first year of life [1]. Progressive sensorineural hearing loss presents in the first decade in as many as 70% of patients and may be detected as early as one year of age [1]. Infantile DCM is observed in approximately 60% of patients and diabetes, hepatic and renal dysfunction can present later in life [2].

AS is caused by mutations in *ALMS1*, a large gene comprising 23 exons. Most affected individuals are compound heterozygotes, having mutations involving one or more of exons 8 (25%), 10 (27%) and 16 (41%) which are referred to as the “mutational hotspots” [3] and [4]. A screening strategy that first targets the mutational hotspots has been successfully used [5]. Given the heart and eye involvements in the current patients, a diagnosis of AS was considered. Linkage analysis with microsatellite markers showed that the siblings shared the same haplotype at the *ALMS1* locus and diagnostic sequencing of *ALMS1* mutational hotspots was undertaken. No pathogenic variants were identified. At the time of testing, complete gene sequencing was only pursued in cases where at least one pathogenic variant was identified in a mutation hotspot. Due to the absence of variants in the *ALMS1* mutational hotspots and the atypical presentation in these siblings, the AS diagnosis was excluded. Extensive investigations subsequently excluded a wide differential but the cause of the disorder remained unknown. We undertook whole exome sequencing to identify the recessive gene responsible for the DCM and retinopathy in this family.

## **2. Methods**

### **2.1. Consent**

Written informed consent was obtained from the patient's parents and the study was approved by the ethics committee of Temple Street Children's University Hospital, Ireland.

### **2.2. Exome sequencing**

Exome sequencing was performed on genomic DNA from one affected child (II:2). Libraries were prepared and hybridised with the Sure Select 50 Mb Human All Exon capture probes (Agilent Technologies, Santa Clara). The enriched libraries were sequenced on an Illumina Hi Seq at GATC (Konstanz, Germany). The paired-end reads were aligned to the hg18 reference genome with the Burrows-Wheeler Alignment tool 0.5.7 [6]. Reads of inadequate sequence quality and potential PCR duplicates were discarded. The quality scores for the aligned reads were recalibrated using GATK [7]. Regions containing clusters of SNPs were identified and the reads in these regions were realigned using GATK. Variants and indels were identified using SAMtools [8]. Assuming an autosomal recessive model, we prioritised variants that were (i) autosomal, (ii) homozygous or potential compound heterozygous, (iii) not present in dbSNP130, (iv) absent or present with a frequency <1% in our 50 Irish control exomes, (v) located within a SNP linkage interval identified using Merlin (data not shown) and (vi) absent or present with a frequency <1% in the NHLBI Exome Variant Server database.

### **2.3. *ALMS1* validation**

PCR amplification and Sanger sequencing of the amplicons were used to validate the *ALMS1* NM\_015120.4 variants identified by exome sequencing (Supplementary Table S1).

### **3. Results**

#### **3.1. Clinical Report**

##### **3.1.1. Patient II:1**

Patient II:1 was born at term following an uneventful pregnancy weighing 4.195 kg. At 10 days old she was noticed to be a slow feeder. At 4 ½ weeks she was admitted to hospital with a 2/3 day history of lethargy, poor oral intake and respiratory and cardiac distress and a diagnosis of dilated cardiomyopathy was made. She was commenced on diuretics and digoxin and subsequently improved. At 9 months, her heart function had almost normalised. She was commenced on an ACE inhibitor at age 8 years and has stable cardiac function. During the first few years of life, she experienced recurrent upper respiratory tract infections, but these have lessened with time.

She was noted to have poor eyesight at 2 years of age and had a reduction in her field of vision. She was prescribed glasses for astigmatism. Although the retinae appeared normal, electroretinography showed a flat response, confirming a cone-rod dystrophy. The visual acuity and the electrophysiology suggested that the cones were more affected than the rods, although the rods system was also significantly affected. Significant visual impairment was diagnosed at the age of 6 years. Her central vision continues to deteriorate but the peripheral vision remains satisfactory. Currently, at aged 11 years, she has no visual phenomena. An MRI brain scan was essentially normal. Metabolic investigations were all within normal limits.

At age 6 years 4 months her weight was 24.4 kg (75<sup>th</sup> centile), height 119.6 cm (75<sup>th</sup> centile) and head circumference 51 cm (<50<sup>th</sup> centile). Repeat measurements performed aged 11 years showed a weight of 43.2 kg (90<sup>th</sup> centile), height of 150.4 cm (90<sup>th</sup> centile) and head

circumference of 52.2 cm (<50th centile). Her Body Mass Index is 18. General physical examination including examination of the heart, lungs, abdomen, tone and reflexes was normal. She has no dysmorphic features. Her general health is good. Abdominal and pelvic ultrasound was normal. She has dyslexia (10<sup>th</sup> percentile for reading), requires a special needs assistant in school and receives 3 hours resource teaching a week.

### **3.1.2. Patient II:2**

Patient II:2 was sent for cardiac assessment at 12 weeks of age because of his sister's history. This revealed a dilated cardiomyopathy and he was treated with diuretics and digoxin. He was taken off digoxin at age 5 years and commenced on an ACE inhibitor and an  $\alpha/\beta$  blocker. His left ventricle however remains enlarged on echocardiogram. Ophthalmology assessment at age 1 years and 2 months he was noted to be mild hyperopic with symmetrical degree of astigmatism. A follow up visit at age 1 year and 7 months showed that vision in both eyes was 6/12 equivalent with Cardiff Cards. At this time, the refraction was quite less hyperopic but a significant astigmatic component remained. Ophthalmologic examination found no specific features of metabolic or mitochondrial problems. He has a history of recurrent upper respiratory tract infections. He had a tonsil and adenoidectomy done and grommets inserted aged 4 years. At age 3 years 7 months his weight was 17.4 kg (75<sup>th</sup> centile), height 104 cm (75<sup>th</sup> centile) and head circumference 51.5 cm (50<sup>th</sup> centile). At his most recent review, aged 9 years, the patients' head circumference was 54.1 cm (<50<sup>th</sup> centile), weight was 31 kg (<75<sup>th</sup> centile) and height 137.4 cm (75<sup>th</sup> centile). His Body Mass Index is 16.6. General physical examination including examination of the heart, lungs, abdomen, gait, tone and reflexes was normal.

### **3.2. Exome sequencing**

To identify the gene responsible for the DCM and retinopathy in this family we undertook exome sequencing of one affected child (II:2) (Supplementary Table S2). Assuming an autosomal recessive model, our prioritisation strategy identified a single candidate gene, *ALMS1* (Supplementary Table S3). Both affected children share two novel compound heterozygous frameshift mutations; a paternally-inherited deletion in exon 5 (c.777delT:p.D260fs\*26) and a maternally-inherited insertion in exon 20 (c.12145\_12146insC:p.S4049fs\*36) (Fig. 2). Validation and segregation of the *ALMS1* variants with the disease phenotype was confirmed by Sanger sequence analysis (Fig. 3).

### **3.3. Follow-up clinical investigations**

The patients underwent general paediatric review following confirmation of the Alstrom diagnosis (Table 1). Cardiac function remains satisfactory with current medication. Both children have visual impairment which is more severe in the older affected child (II:1). Importantly, both children are not overweight. Their Body Mass Index (BMI) is in the normal range. In the affected female (II:1), pulmonary function tests indicated mild small airways disease/asthma. This was not noted in the affected male (II:2). Initial testing in the affected female (II:1) showed abnormal liver function tests which have normalised over the past 6 months. A very mild coagulation abnormality with normal synthetic function was also detected in both patients but was considered to be drug-related. A hearing test showed a slight dip at high frequencies within normal thresholds in II:1 which is asymptomatic. The hearing test in II:2 was normal.

## **4. Discussion**

Clinical diagnostic criteria are essential tools to aid the clinician to determine when and when not to order expensive genetic tests. However, clinical diagnostic criteria for disorders such

as Rett and Beckwith-Wiedemann syndrome have become obsolete as it became apparent that many cases had mutations in the associated disease genes despite not meeting the diagnostic criteria. When the Alström gene was identified, the size and nature of the gene precluded comprehensive sequencing as a diagnostic test. A testing strategy was adopted which required at least one mutation to be identified in the mutational hotspots before further analysis was pursued. Patients without mutations in the hotspots were re-assessed clinically and alternative diagnoses pursued. We have identified novel compound heterozygous truncating mutations in *ALMS1*, the gene associated with Alström Syndrome, in non-consanguineous Irish siblings with an atypical presentation. The absence of a number of key clinical features (obesity, nystagmus, photophobia, short stature and hearing loss) together with the absence of a mutation in the *ALMS1* hotspots had initially deterred us from this diagnosis. Our study suggests that the current clinical diagnostic criteria and genetic testing strategy will miss atypical cases.

Similar to the reported AS disease mutations, the mutations identified in the patients in the current study (a deletion in exon 5 and an insertion in exon 20) are also frameshift and result in premature protein truncation. The exon 5 deletion causes frameshift at residue 260 and introduces a premature stop codon at residue 284. The resulting truncated protein lacks 3,908 wild-type amino acids (93.8%) and is predicted to undergo non-sense mediated decay. The 1 base-pair insertion in exon 20 causes frameshift at residue 4049 and premature termination at residue 4081. Although located at the C-terminus of the transcript, the frameshift occurs directly within the ALMS motif (residues 4035-4167) which is part of the C-terminal portion of *ALMS1* that contributes to centrosome targeting. Examination of *ALMS1* localization to the centrosomes by Knorz and colleagues showed that constructs lacking the 3' end (3176-4167) of *ALMS1* show diffuse or less compact chromosomal staining and constructs missing

from residues 5 onwards show no detectable centrosomal staining [9]. Therefore, based on the work of Knorz and colleagues, it is likely that both mutant proteins identified in the affected siblings will show reduced or absent localization to the centrosomes.

The variants identified in our patients are outside of the mutational hotspots and are the first report of mutations in *ALMS1* exons 5 and 20 [10]. Review of the EURO-WABB *ALMS1* LOVD genetic database and PubMed identified four patients with two pathogenic *ALMS1* variants, both located outside of the *ALMS1* mutation hotspots (Supplementary Table S4). The phenotype of these four patients (with variants in exons 6, 11, 17 and 18) is different from the patients reported in the current study (with variants in exons 5 and 20) but also deviates from the classical AS presentation; one or more common AS features are absent and additional non-AS features are present in some patients. The spectrum of clinical features in patients with two variants outside of the commonly mutated *ALMS1* exons 8, 10 and 16 varies greatly and no genotype-phenotype correlation is apparent. We hypothesise that the nature and location of the *ALMS1* mutations may account for the atypical presentation in the siblings reported in this study. It is plausible that the milder phenotype of the siblings described here relates to this mutation in exon 20 which is located towards the 3' end of the 23 exon *ALMS1* gene. Three *ALMS1* isoforms have been reported with different tissue-specific expression and function [11]. *ALMS1* isoform 3 lacks exon 20 (one of the exons mutated in these children). It is possible that expression of *ALMS1* isoform 3 in the brain results in a mixture of wild-type (isoform 3 lacking exon 20 mutation) and mutant *ALMS1* protein in these tissues, possibly sparing the patients from obesity and hearing loss.

Childhood-onset obesity is a cardinal feature of AS and a normal BMI (<25 kg/m<sup>2</sup>) is extremely rare. Childhood hyperphagia has been suggested as a possible issue contributing to

obesity, although the evidence remains anecdotal [1] and [12]. It has been proposed that a defective *ALMS1* protein in the brain and pancreas could impair normal functioning of satiety factors leading to overeating [5]. Another possible explanation for childhood obesity in AS relates to the role of *ALMS1* in ciliary function. Obesity in ciliopathic syndromes suggests cilia are utilised in the neural circuitry that monitors food intake [13]. There have been three published reports of patients with AS but without obesity, although the specific *ALMS1* mutations in the patients were not reported [5] and [14].

To our knowledge, this is the first report of AS without nystagmus, photophobia, obesity and hearing loss. Although the updated 2013 guidelines recommend sequencing of all *ALMS1* exons, the patients in our study do not meet the criteria for a clinical diagnosis of AS (due to absence of photophobia) and hence would not warrant *ALMS1* sequencing under current guidelines [4]. The atypical presentation in the siblings described here suggests that the diagnostic criteria for AS may need to be broadened to include patients with an isolated eye and heart phenotype. Our study expands the clinical spectrum associated with *ALMS1* mutations and supports complete *ALMS1* gene sequencing in children that present with infantile cardiomyopathy and retinopathy, even in the absence of the full complement of classical AS features.

### **Conflict of interest**

The authors declare no conflict of interest.

### **Acknowledgements**

We sincerely thank the participating family for the use of genetic samples and clinical information. This study was supported by the Children's Fund for Health, The Fundraising

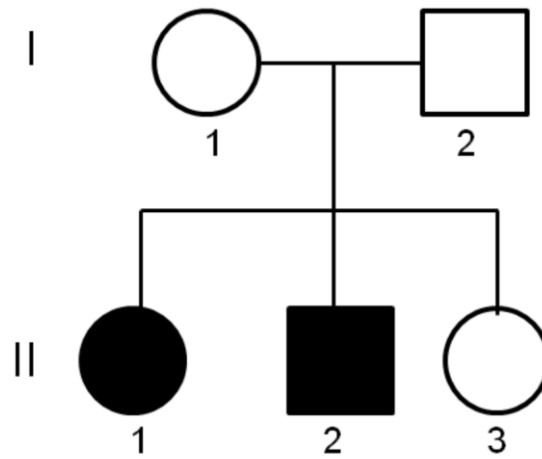
Office for Temple Street Children's University Hospital, Dublin, Ireland (PAC10175) and a Medical Research Charities Group grant (MRCG/2011/17) from the Health Research Board (Ireland) and the National Children's Research Centre (Our Lady's Children's Hospital, Crumlin, Ireland). Jillian Casey is also supported by a Medical Research Charities Group grant (MRCG/2011/17).

### **Web Resources**

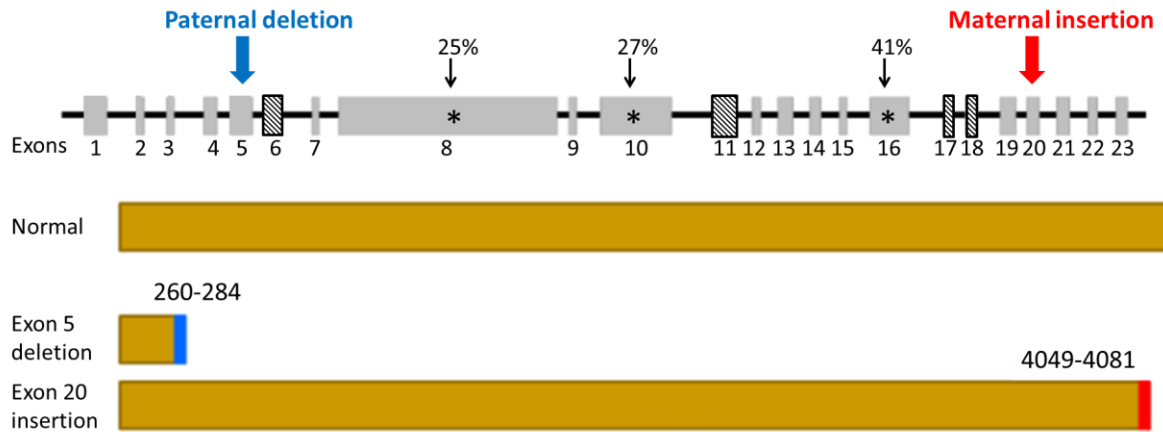
dbSNP130: [http://www.ncbi.nlm.nih.gov/projects/SNP/snp\\_summary.cgi?build\\_id=130](http://www.ncbi.nlm.nih.gov/projects/SNP/snp_summary.cgi?build_id=130)

NHLBI Exome Variant Server database: <http://evs.gs.washington.edu/EVS/>

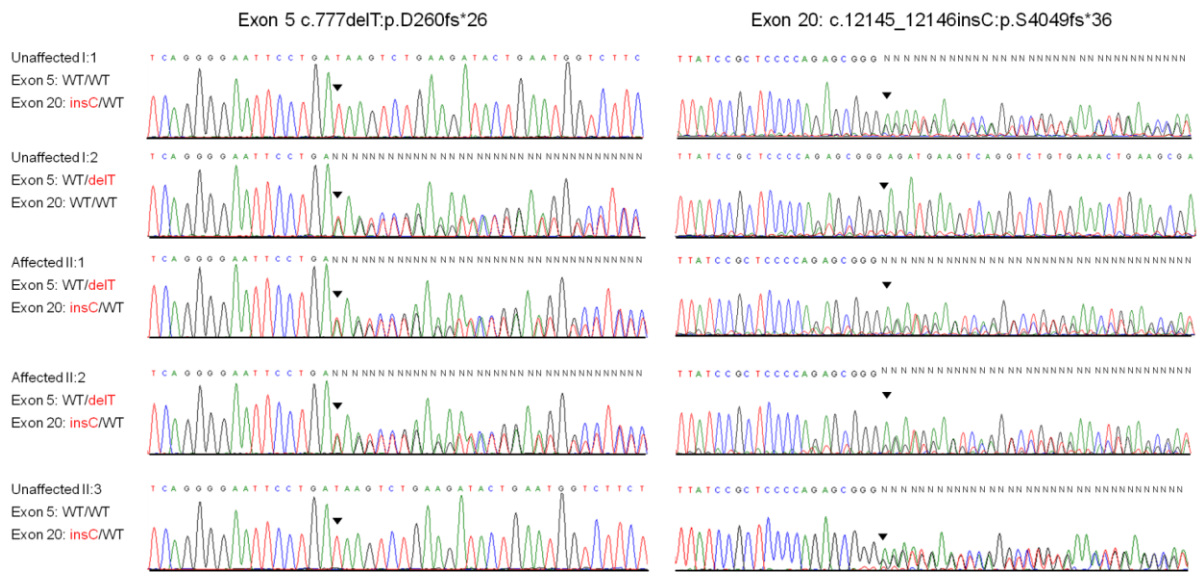
## Figures



**Fig. 1. Family pedigree.** A non-consanguineous Irish family that includes two children (female and male) presenting with an infantile dilated cardiomyopathy and cone-rod dystrophy.



**Fig. 2. Schematic representation of *ALMS1* mutations.** The paternally-inherited exon 5 deletion causes frameshift at residue 260 and introduces a premature stop codon at residue 28, eliminating 3,908 wild-type amino acids. The maternally-inherited insertion in exon 20 causes frameshift at residue 4049 and premature termination at residue 4081. The frameshift occurs directly within the ALMS motif (residues 4035-4167). The *ALMS1* mutational hotspots are denoted with a \*. Four reported patients have two *ALMS1* variants (homozygous or compound heterozygous) outside of the mutational hotspots. The exonic location of these atypical variants is denoted with cross-hatching and the exons are outlined in bold.



**Fig. 3. Sanger sequence validation of *ALMS1* frameshift mutations.** Both affected children are compound heterozygous for a paternally inherited 1 base-pair deletion in exon 5 and a maternally inherited 1 base-pair insertion in exon 20 of *ALMS1*. The healthy sibling (II:3) is a carrier of the exon 20 insertion but did not inherit the exon 5 deletion.

**Table 1. Clinical investigations after molecular diagnosis of atypical Alströms**

Test performed	Female II:1	Male II:2	Expected features in Alström Syndrome
	Age 11 years	Age 9 years	
Current weight (kg)	43.2 (90 <sup>th</sup> ctl)	31 (<90 <sup>th</sup> ctl)	Childhood truncal obesity
Current height (cm)	150.4 (90 <sup>th</sup> ctl)	137.4 (75-90 <sup>th</sup> ctl)	Short stature (height <50 <sup>th</sup> ctl)
Current head circumference (cm)	52.2 (<50 <sup>th</sup> ctl)	54.1 (<98 <sup>th</sup> ctl)	Normal
Current body mass index	18 (<10 <sup>th</sup> ctl)	16.6 (<20 <sup>th</sup> ctl)	Increased BMI (>95 <sup>th</sup> ctl)
Alanine aminotransferase (<35 IU/L)	<b>54, 76, 25</b>	22	Elevated; indicative of liver dysfunction
Aspartate aminotransferase (<40 IU/L)	<b>50</b>	23	Elevated; indicative of liver dysfunction
Gamma glutamyl transferase (<25 IU/L)	<b>75, 77, 48</b>	24, 19	Elevated; indicative of liver dysfunction
Alkaline phosphatase (<300 IU/L)	223, 265, 216	176, 207	Elevated; indicative of liver dysfunction
Activated partial thromboplastin time (20.8-30.8)	<b>33.9, 32, 31.5</b>	<b>32.3, 32.5</b>	N/A (indicative of liver dysfunction)
Prothrombin time (9.6-11.8)	<b>12.1, 11.8, 11.9</b>	<b>12.1, 11.9</b>	N/A (indicative of liver dysfunction)
Fasting lipid profile (cholesterol and triglycerides)	Normal	Normal	Elevated triglycerides and cholesterol

Renal function (sodium, creatinine, potassium, urea)	Normal	Normal	Elevated; indicative of renal dysfunction
--	--------	--------	---

General paediatric reviews relevant to Alström Syndrome were undertaken following identification of the *ALMS1* variants. The normal ranges are reported in brackets in the left-hand column. Measurements outside of the normal range are shown in bold. Repeat tests were performed five weeks apart. Abbreviations: ctl; centile.

## References

- [1] J.D. Marshall, R.T. Bronson, G.B. Collin, A.D. Nordstrom, P. Maffei, R.B. Paisey, C. Carey, S. Macdermott, I. Russell-Eggitt, S.E. Shea, J. Davis, S. Beck, G. Shatirishvili, C.M. Mihai, M. Hoeltzenbein, G.B. Pozzan, I. Hopkinson, N. Sicolo, J.K. Naggert, P.M. Nishina. New Alstrom syndrome phenotypes based on the evaluation of 182 cases. *Arch Intern Med* 2005;165:675-683
- [2] A.N. Makaryus, B. Popowski, S. Kort, Y. Paris, J. Mangion. A rare case of Alstrom syndrome presenting with rapidly progressive severe dilated cardiomyopathy diagnosed by echocardiography. *J Am Soc Echocardiogr* 2003;16:194-196
- [3] J.D. Marshall, E.G. Hinman, G.B. Collin, S. Beck, R. Cerqueira, P. Maffei, G. Milan, W. Zhang, D.I. Wilson, T. Hearn, P. Tavares, R. Vettor, C. Veronese, M. Martin, W.V. So, P.M. Nishina, J.K. Naggert. Spectrum of *ALMS1* variants and evaluation of genotype-phenotype correlations in Alstrom syndrome. *Hum Mutat* 2007;28:1114-1123
- [4] J.D. Marshall, P. Maffei, S. Beck, T.G. Barrett, R. Paisey, J.K. Naggert. Clinical utility gene card for: Alstrom Syndrome - update 2013. *Eur J Hum Genet* 2013;21

- [5] J.D. Marshall, P. Maffei, G.B. Collin, J.K. Naggert. Alstrom syndrome: genetics and clinical overview. *Curr Genomics* 2011;12:225-235
- [6] H. Li, R. Durbin. Fast and accurate short read alignment with Burrows-Wheeler transform. *Bioinformatics* 2009;25:1754-1760
- [7] A. McKenna, M. Hanna, E. Banks, A. Sivachenko, K. Cibulskis, A. Kernytsky, K. Garimella, D. Altshuler, S. Gabriel, M. Daly, M.A. DePristo. The Genome Analysis Toolkit: a MapReduce framework for analyzing next-generation DNA sequencing data. *Genome Res* 2010;20:1297-1303
- [8] H. Li, B. Handsaker, A. Wysoker, T. Fennell, J. Ruan, N. Homer, G. Marth, G. Abecasis, R. Durbin. The Sequence Alignment/Map format and SAMtools. *Bioinformatics* 2009;25:2078-2079
- [9] V.J. Knorz, C. Spalluto, M. Lessard, T.L. Purvis, F.F. Adigun, G.B. Collin, N.A. Hanley, D.I. Wilson, T. Hearn. Centriolar association of ALMS1 and likely centrosomal functions of the ALMS motif-containing proteins C10orf90 and KIAA1731. *Mol Biol Cell* 2010;21:3617-3629
- [10] D. Astuti, T. Barrett. EURO-WABB Project Open Variantion Database: Alstrom syndrome 1 (ALMS1). Accessed 20<sup>st</sup> January 2014
- [11] G.B. Collin, J.D. Marshall, B.L. King, G. Milan, P. Maffei, D.J. Jagger, J.K. Naggert. The Alstrom syndrome protein, ALMS1, interacts with alpha-actinin and components of the endosome recycling pathway. *PLoS One* 2012;7:e37925
- [12] P. Maffei, V. Munno, J.D. Marshall, C. Scandellari, N. Siculo. The Alstrom syndrome: is it a rare or unknown disease? *Ann Ital Med Int* 2002;17:221-228
- [13] A. Louvi, E.A. Grove. Cilia in the CNS: the quiet organelle claims center stage. *Neuron* 2011;69:1046-1060

- [14] E. Koc, G. Bayrak, M. Suher, C. Ensari, D. Aktas, A. Ensari. Rare case of Alstrom syndrome without obesity and with short stature, diagnosed in adulthood. *Nephrology (Carlton)* 2006;11:81-84

## Supplementary Material

**Supplementary Table S1. *ALMS1* Primer sequences**

<b>ALMS1 variant</b>	<b>Primer sequence</b>	<b>Product Size (bp)</b>
Exon5:c.777delT;p.D260fs	Forward 5'-tctgaaattaggagagctgtgtttt-3' Reverse 5'-aagggcactgagaccaac-3'	312
Exon20:c.12145_12146insC;p.S4049fs	Forward 5'-taatctgaggctgggcattt-3' Reverse 5'-tgggctggcctttagcag-3'	314

The nomenclature refers to *ALMS1* NM\_015120.4. The *ALMS1* exons were amplified using a thermal cycler (Biorad tetrad 2 DNA engine) and PCR was performed under the following conditions: incubation at 95°C for 4 mins followed by 35 cycles of denaturation at 95°C for 1 min, annealing at 60°C for 1 min and an extension at 72°C for 1 min followed by a final 5 mins at 72°C.

**Supplementary Table S2. Summary statistics for exome sequence analysis**

<b>ID</b>	<b>Total reads</b>	<b>Uniquely mapped reads</b>	<b>Called bases overlapping with target exons (CCDS)</b>	<b>% CCDS with <math>\geq 1x</math> coverage</b>	<b>% CCDS with <math>\geq 10x</math> coverage</b>	<b>Median fold on-target coverage</b>
<b>II:2</b>	91,632,092	90,655,846	2,832,655,044	99.46	94.70	85

Genomic DNA from the affected male child (II:2) with dilated cardiomyopathy and retinopathy was enriched for exonic DNA using an Agilent Sure Select 50 Mb Human All Exon capture kit. The enriched libraries were sequenced on an Illumina Hi Seq sequencer (Illumina) at GATC (Konstanz, Germany).

**Supplementary Table S3. Prioritisation of exome variants**

<b>Prioritisation Criteria</b>	<b>Homozygous</b>	<b>Potential Compound Heterozygous<sup>a</sup></b>
Coding (missense, nonsense, splice site or indel) and not present in dbSNP130	165 variants	248 variants; 65 genes
+ Absent or present with a frequency <1% in our 50 Irish control exomes	0 variants	10 variants; 5 genes
+ Located in SNP linkage interval (identified using Merlin)	-	4 variants; 2 genes
+ Absent or present with a frequency <1% in NHLBI ESP database	-	2 variants; 1 gene ( <i>ALMS1</i> )

<sup>a</sup>Genes with two or more novel coding variants

Supplementary Table S4. Patients with Alström syndrome who have two *ALMS1* variants outside of the commonly mutated exons

Exon	DNA change	Protein change	State	RDY	NYS	PP	CM	OBS	SS	HL	T2DM	LD	RD	Additional features and references
<b>11</b>	c.9749C>A	p.S3250*	hom	+	NR	NR	+	-	NR	+	-	+	-	Febrile convulsions, neuro-anatomical brain anomalies, abnormal thickening of gallbladder wall <sup>1</sup>
<b>18i</b>	c.11876-3T>G	p.V3960Ifs*8	hom	+	-	NR	no	No	no	+	-	+	-	Ketoacidotic insulin-dependent diabetes (T1), optic atrophy, frequent seizures <sup>2</sup>
<b>18i</b>	c.11876-2A>T	p.V3960Ifs*8	hom	+	NR	NR	-	+	+	NR	+	NR	NR	None reported <sup>3</sup>
<b>6</b>	c.1270G>A	p.V424I	c het	+	NR	NR	NR	+	NR	-	+	NR	+	Hirsutism present on the face, abdomen, and arms <sup>4</sup>
<b>17</b>	c.11644C>T	p.H3882Y												
<b>5</b>	c.777delT	p.D260fs*26	c het	+	-	-	+	-	-	-	-	-	-	None (current study)
<b>20</b>	c.12145_12146insC	p.S4049fs*36												

Clinical and genetic information for Alström patients who have two pathogenic variants outside of the *ALMS1* mutation hotspots. A review of the EURO-WABB *ALMS1* LOVD database (Jan 20<sup>th</sup> 2014) identified four patients, in addition to the patients reported in the current study, with two pathogenic *ALMS1* variants located outside of exons 8, 10 and 16 (mutational hotspots). Abbreviations: hom; homozygous, c het; compound heterozygous, +; feature present, -; feature absent, i; intronic, NR; feature not reported in publication, RDY; retinal dystrophy with vision loss, NYS; nystagmus, PP; photophobia, CM; cardiomyopathy, OBS; obesity, SS; short stature, HL; hearing loss, T2DM type 2 diabetes mellitus, LD; liver dysfunction, RD; renal dysfunction.

## References

- [1] S. Taşdemir, A. Güzel-Ozantürk, J.D. Marshall, G.B. Collin, R.K. Özgül, N. Narin, M. Dündar, J.K. Naggert. Atypical Presentation and a Novel Mutation in ALMS1: Implications for Clinical and Molecular Diagnostic Strategies for Alström Syndrome. *Clin Genet* 2013; 83(1): 96–98
- [2] M. Sanyoura, C. Woudstra, G. Halaby, P. Baz, V. Senée, P.J. Guillausseau, P. Zalloua, C. Julier. A novel ALMS1 splice mutation in a non-obese juvenile-onset insulin-dependent syndromic diabetic patient. *Eur J Hum Genet* 2013; 22:140-143
- [3] M.A. Aldahmesh, L. Abu-Safieh, A.O. Khan, Z.N. Al-Hassnan, R. Shaheen, M. Rajab, D. Monies, B.F. Meyer, F.S. Alkuraya. Allelic heterogeneity in inbred populations: the Saudi experience with Alström syndrome as an illustrative example. *Am J Med Genet A* 2009;15:149A(4):662-665
- [4] T. Joy, H. Cao, G. Black, R. Malik, V. Charlton-Menys, R.A. Hegele, P.N. Durrington. Alstrom syndrome (OMIM 203800): a case report and literature review. *Orphanet J Rare Dis* 2007; 2:49

