



<b>Title</b>	Is there a role for Placental Volume, Vasculature and Calcification in monitoring Post-term Pregnancies?
<b>Authors(s)</b>	Moran, Mary, Zombori, Gergely, Ryan, John, Downey, P., McAuliffe, Fionnuala M.
<b>Publication date</b>	2014-06-01
<b>Publication information</b>	Moran, Mary, Gergely Zombori, John Ryan, P. Downey, and Fionnuala M. McAuliffe. "Is There a Role for Placental Volume, Vasculature and Calcification in Monitoring Post-Term Pregnancies?" BMJ Publishing Group, June 1, 2014. <a href="https://doi.org/10.1136/archdischild-2014-306576.247">https://doi.org/10.1136/archdischild-2014-306576.247</a> .
<b>Publisher</b>	BMJ Publishing Group
<b>Item record/more information</b>	<a href="http://hdl.handle.net/10197/7661">http://hdl.handle.net/10197/7661</a>
<b>Publisher's version (DOI)</b>	10.1136/archdischild-2014-306576.247

Downloaded 2026-05-01 23:46:10

The UCD community has made this article openly available. Please share how this access benefits you. Your story matters! (@ucd\_oa)



© Some rights reserved. For more information

# Is there a role for assessment of Placental Volume, Vasculature and Calcification in monitoring Post-term pregnancies?

Moran M<sup>1</sup>, Zombori G<sup>1</sup>, Ryan J<sup>1</sup>, Downey P<sup>2</sup>, McAuliffe FM<sup>2</sup>

<sup>1</sup>Diagnostic Imaging, School of Medicine and Medical Science, University College Dublin, Dublin, Ireland, <sup>2</sup>UCD Obstetrics and Gynaecology, School of Medicine and Medical Science, UCD, National Maternity Hospital, Dublin, Ireland

## Objectives

The risk of fetal and maternal complications increases when pregnancy advances beyond 40 weeks gestation. These complications include moderate or thick meconium stained liquor, an Apgar score of  $\leq 6$  at 5 minutes, fetal macrosomia, instrumental vaginal delivery, chorioamnionitis and admission to the neonatal intensive care unit. Associated complications when the pregnancy advances beyond 41 weeks also include intrauterine fetal death (2.5 times greater than before 40 weeks), neonatal death, endomyometritis and caesarean section [1,2]. Also it is normal for placental calcification to increase as the fetus approaches term, and extensive calcification is common after 40 weeks [3].

Due to the associated risks increased antenatal surveillance is required at this stage. Hospitals and clinicians differ in relation to the gestation at which they arrange an ultrasound scan to assess fetal wellbeing when a pregnancy is prolonged. It is the policy at the study hospital for all women who are not delivered by 41+5 weeks gestation to have a scan (to check fetal presentation, biophysical profile and placental site) and each case is managed based on the scan findings.

This study aims to assess if three dimensional power Doppler (3DPD) of the placenta, evaluating placental volume, vascularisation, and blood flow in post-term pregnancies differs from normal and can therefore provide additional information to the clinician. It also examines whether or not a new software tool (the placentometer) identifies the increased calcification normally present in the placenta after 40 weeks gestation.

## Methods

This was a prospective cohort study involving 50 women with post-term pregnancies. Each patient had one scan and gestational age at the time of the scan ranged from 40+1 to 41+6 weeks. 3DPD ultrasound was used to calculate placental volume, vascularisation index (VI), flow index (FI) and vascularisation-flow index (VFI). This was done using the Virtual Organ Computer-aided Analysis (VOCAL™) software, employing a previously described method (figure 1) [4]. Following each scan the percentage of calcification was also calculated by computer analysis (figure 2). This was done using a software-assisted grading tool (placentometer), which involves initial delineation of the placental outline, then using a slider technique defining a high intensity threshold to quantify calcification. The overall percentage of calcification is then calculated [5]. The study parameters were analysed for both changes with gestational age within the post-term group and for comparisons with normal pregnancy (n=58; 36-40 weeks) [5]. They were also correlated with the mean uterine artery Doppler pulsatility index (UtA PI), and the presence of a bilateral notch, middle cerebral artery (MCA) PI and umbilical artery (UA) PI, and placental histology.

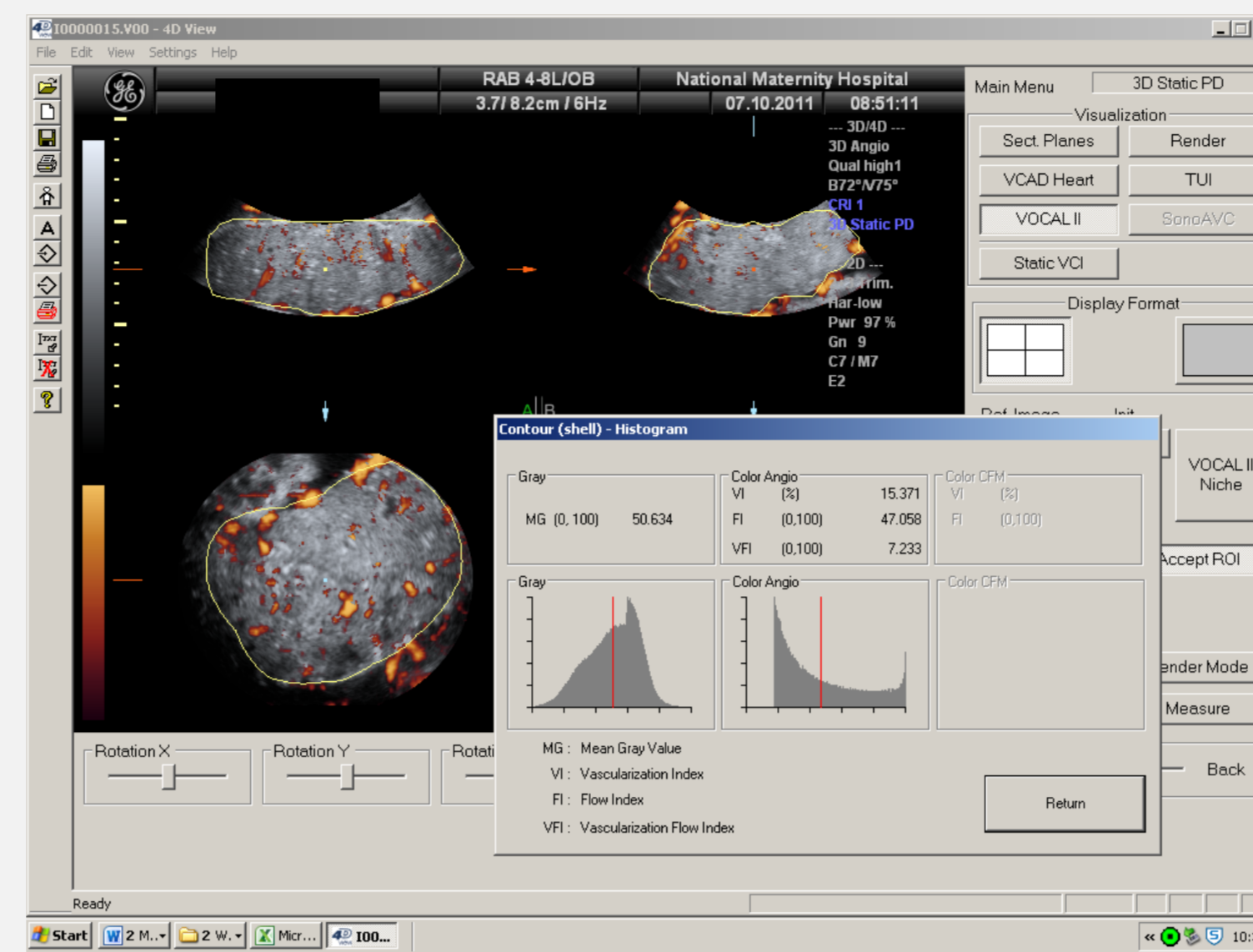


Figure 1: 3D power Doppler histogram demonstrating the placental vascular indices [VI( 15.371%), FI (47.058) and VFI (7.733)]

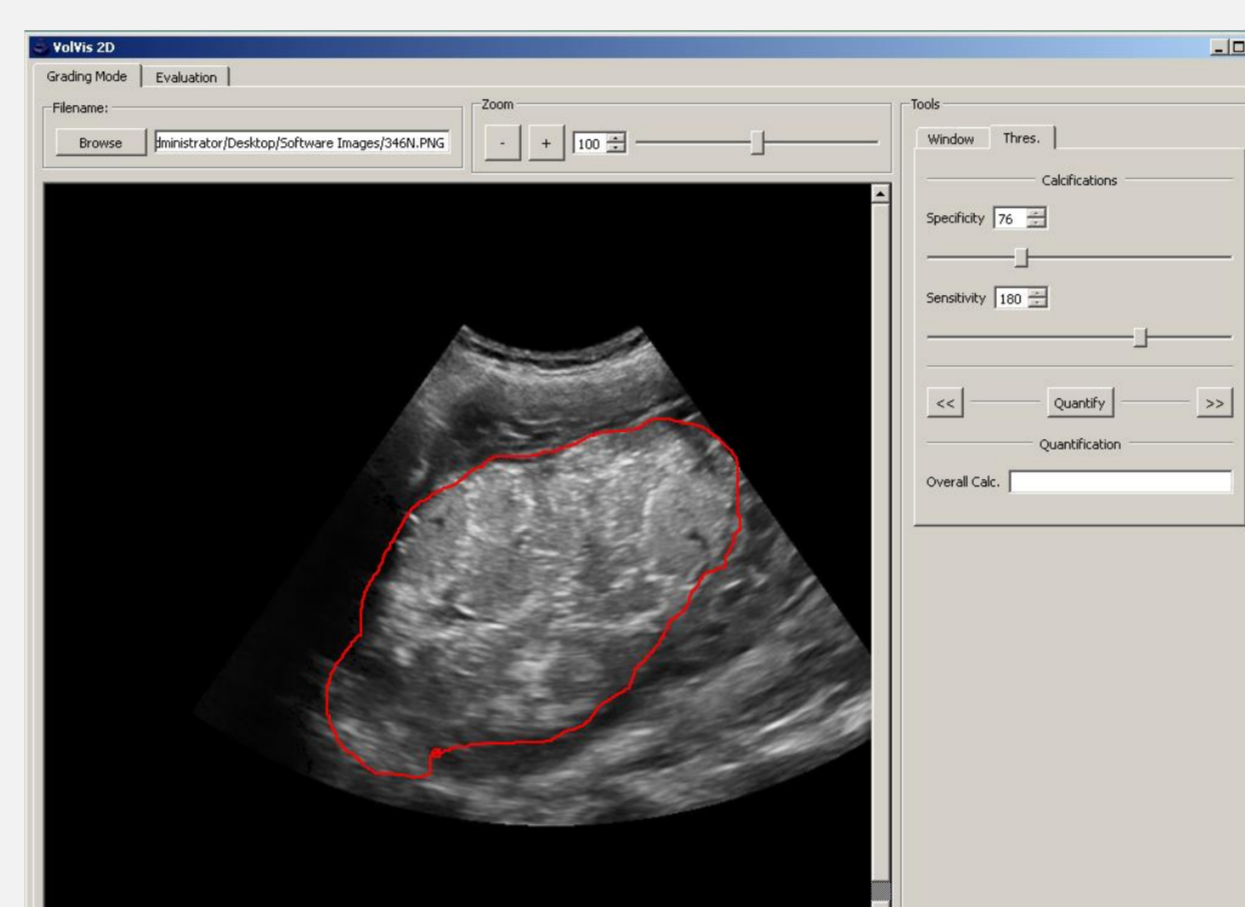


Figure 2a: Placental outline as defined manually using the placentometer (41+1 weeks gestation)

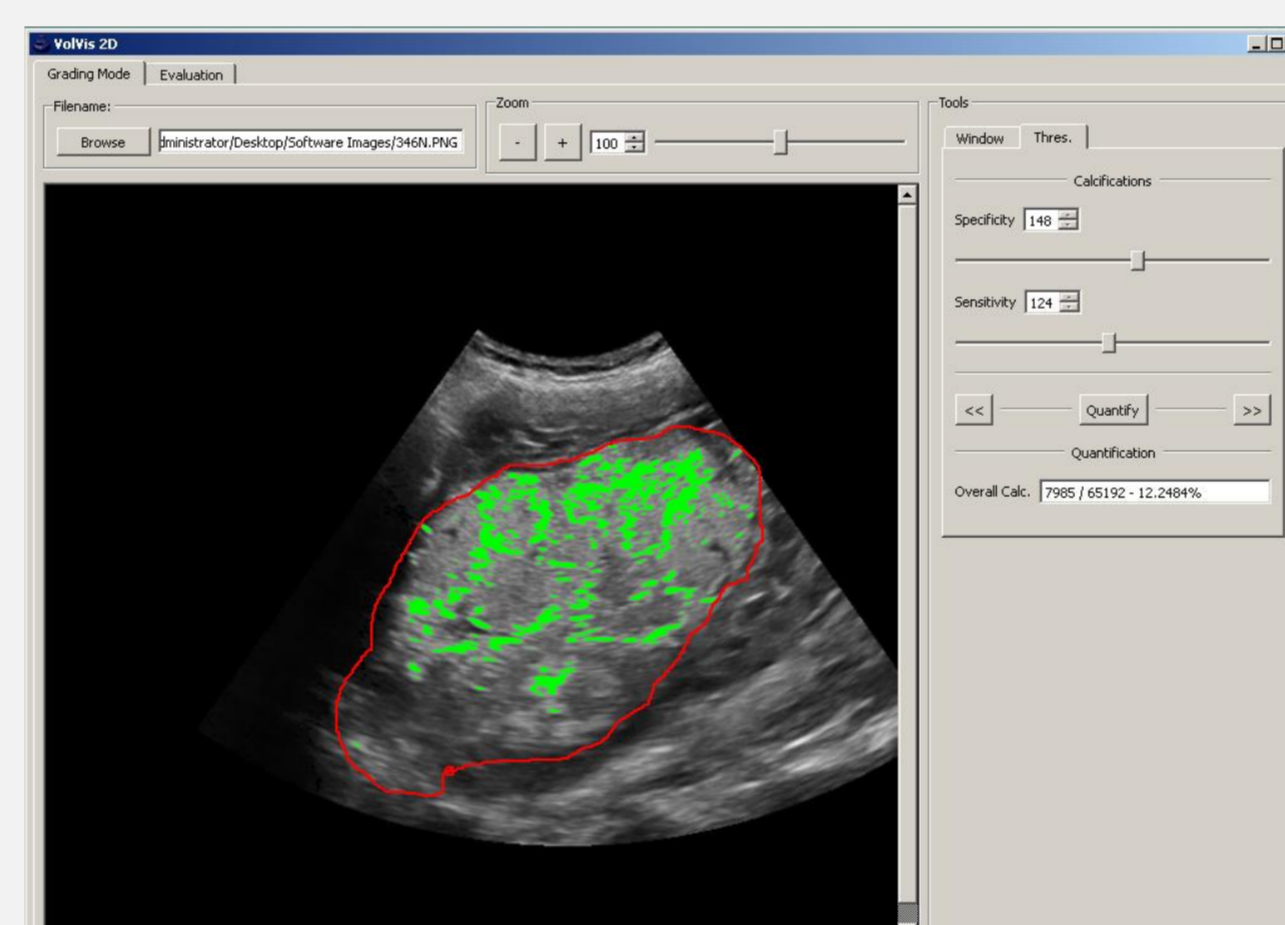


Figure 2b: Definition of the placenta, with the higher intensity areas (representing calcification) highlighted in green.

UtA PI centile value	Number of cases (n=50)	Mean volume cm <sup>3</sup> (SD)
$\leq 5^{\text{th}}$ and $< 50^{\text{th}}$ centile	23	275.80 (174.81)
$\geq 50^{\text{th}}$ and $< 95^{\text{th}}$ centile	17	191.04 (76.08)
$\geq 95^{\text{th}}$ centile	10	158.80 ((76.08)

Table 1: Correlation of the mean placental volume and UtA PI centile ranges in post-term pregnancies ( $p=0.047^*$ )

Chorangiomas	Number of cases	Mean FI (SD)
Absent	35	49.61 (4.94)
Present	15	46.05 (5.83)

Table 2: Comparison of the mean placental FI and the presence or absence of chorangiomas in post-term pregnancies ( $p=0.033^*$ )

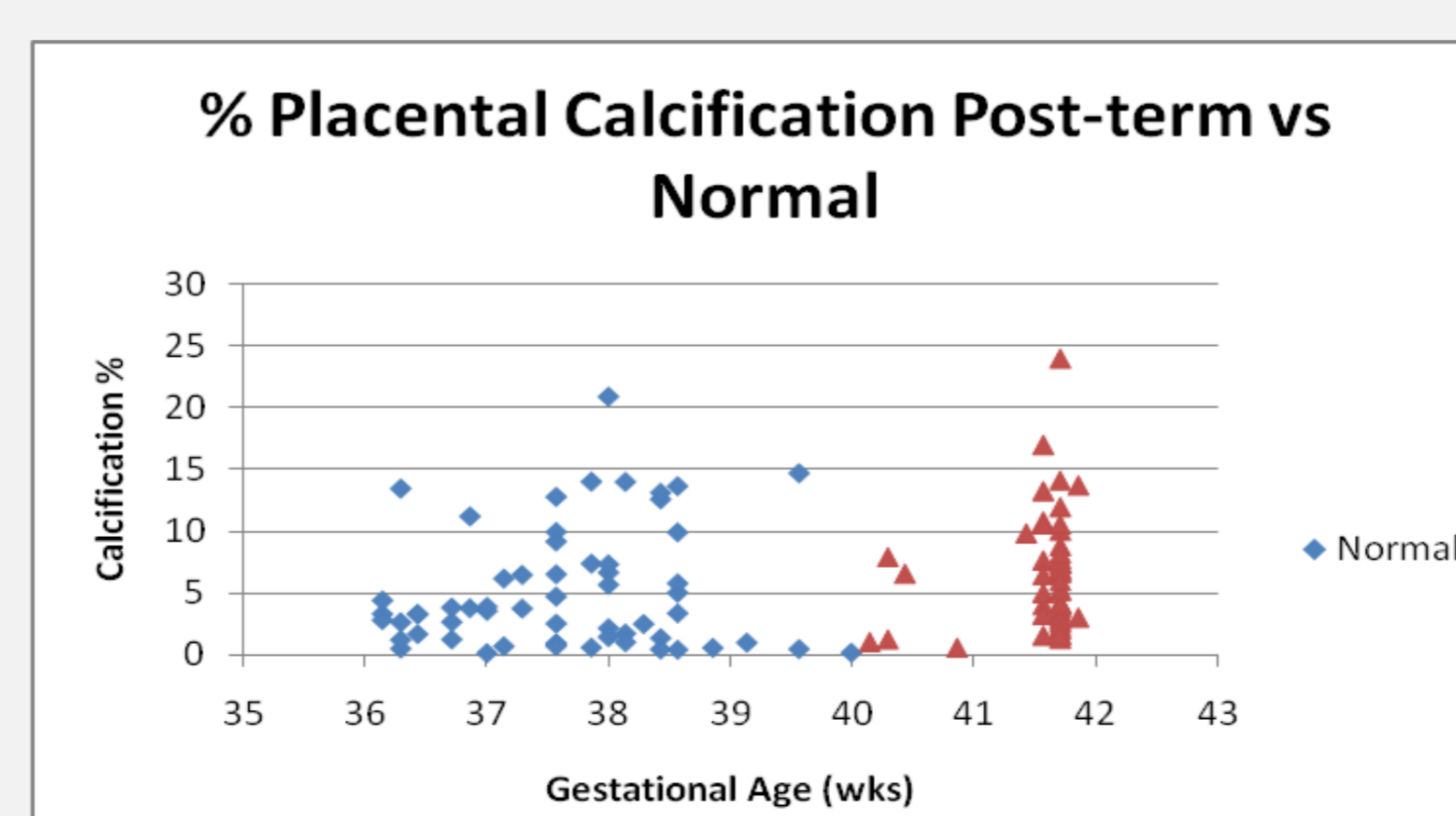


Figure 3: Scatterplot comparing the percentage of placental calcification in post-term and normal pregnancies (36-42 weeks gestation)

## Results

This study showed that placental volume, VI, FI and VFI are not influenced by gestation when the pregnancy has advanced beyond 40 weeks. It was also found that 3DPD placental parameters are similar between post-term pregnancies and normal pregnancies (36-40 weeks).

It was found however that as the UtA PI increased the placental volume decreased ( $p=0.047$ ) (table 1). Independent sample t-test analysis of the study parameter mean values in relation to histology showed that the FI was reduced ( $p=0.033$ ) in placentas where there was a histological diagnosis of chorangiomas (table 2). In cases with no chorangiomas the mean flow index was 49.61 (SD 4.94) as opposed to 46.05 (SD 5.83) when chorangiomas was present.

The mean percentage of placental calcification in the post-term group was 6.44 (SD 4.60) and was higher ( $p=0.014$ ), than the mean in the normal group which was 5.13 (SD 4.86) (figure 3). Computerised analysis of calcification also showed that calcification continues to increase between 40 and 42 weeks ( $p=0.029$ )

## Conclusion

This study showed no difference in placental volume, VI, FI and VFI between pregnancies which have advanced beyond 40 weeks and normal, low-risk pregnancies of 36-40 weeks. It was noted that mean placental flow rate was reduced in cases where chorangiomas was found at histology. Placentas with chorangiomas have an increased number of blood vessels in the chorionic villi. This can be due to either under perfusion of the placenta or a low-grade tissue hypoxia. The lower FI would therefore be explained by the increase in vessel number.

The higher percentage of calcification seen in the post-term pregnancies in our study suggest that our computerised method correctly identifies calcification within the placenta.

The study findings suggest that computerised assessment of calcification and 3DPD placental assessment may provide additional information regarding the health of the placenta, and ultimately the health of the fetus, when performing fetal surveillance after 40 weeks gestation.

## References

- [1] Caughey AB, Musci TJ. Complications of Term Pregnancies Beyond 37 Weeks of Gestation. *Obstet Gynecol* 2004;103(1):57-62 .
- [2] Hilder L, et al. Prolonged pregnancy: evaluating gestation-specific risks of fetal and infant mortality. *BJOG* 1998;105:169-73.
- [3] Abramowicz JS, Sheiner E. Ultrasound of the Placenta: A Systematic Approach. Part 1: Imaging. *Placenta* 2008;29:225-40..
- [4] de Paula et al. Quantitative analysis of placental vasculature by three-dimensional power Doppler ultrasonography in normal pregnancies from 12 to 40 weeks of gestation. *Placenta* 2009;30:142-8.
- [5] Moran M, et al. 3D Power Doppler ultrasound and computerised placental assessment in normal pregnancy. 2014;20:112-6.