

Short Communications

Atypical cutaneous actinobacillosis in young beef cattle

S. D. Cahalan, L. Sheridan, C. R. Akers,
I. Lorenz, J. Cassidy

ACTINOBACILLOSIS is a sporadic, inflammatory disease of the soft tissue in cattle, sheep, goats (Swarbrick 1967, Fubini and Campbell 1983, Muhammad and others 2006, Radostits 2007) and other species (Dibb and others 1981, Carmalt and others 1999, Kennerman and others 2006). The causative organism, *Actinobacillus lignieresii*, is part of the oral flora (Rycroft and Garside 2000, Quinn 2002) and invades mucosal surfaces following trauma caused by abrasive ingesta or the action of the teeth during mastication (Radostits 2007). In cattle, the disease typically involves the formation of pyogranulomas in the oral cavity, tongue or fore-stomachs with subsequent spread to regional lymph nodes (Hebeler and others 1961, Mortimer 1962, Rycroft and Garside 2000), although the skin of the head, neck and, occasionally, the limbs can also be affected. An unusual presentation of the disease is reported here where extensive distal limb involvement resulted in severe lameness in 20 of 130 animals on a beef fattening unit.

The cases occurred in a group of one- to two-year-old Aberdeen Angus crossbred cattle over an 11-month period from when the animals were housed in October 2009 until the following August 2010. Affected animals were housed in groups of 30 to a pen in slatted units at a stocking density of 1 animal/2 metre².

The cases presented clinically as focally extensive unilateral firm swellings distal to the elbow/stifle regions of the fore and hind limbs, resulting in significant lameness. In three animals, multiple limbs were involved. Affected animals lost varying degrees of body condition over a number of weeks due to reduced mobility. All affected animals were treated with parenteral antibiotics including seven-day treatments of penicillin-streptomycin (*Penstrep*, Norbrook) and five-day treatments of amoxicillin-clavulanic acid (*Noroclav*, Norbrook). Approximately 40 per cent of treated cases recovered sufficiently for the animals to be sent for slaughter, 40 per cent improved transiently before relapsing once treatment was terminated, and in the remaining 20 per cent, there was no response to treatment.

Two Aberdeen Angus-cross bullocks, (a yearling, animal A and two year old, animal B), exhibiting typical distal limb lesions which had received no treatment, were referred to the University Veterinary Hospital, University College Dublin for further investigation. On clinical examination, both animals were in good body condition and had non-weight-bearing lameness of their affected limbs. Extensive firm swellings extending from the right stifle to the coronary band were noted in both animals (Fig 1). These animals were euthanased on welfare grounds and submitted for necropsy examination.

Veterinary Record (2012)

doi: 10.1136/vr.100906

S. D. Cahalan, MVB,
L. Sheridan, MVB,
C. R. Akers, BVSc,
I. Lorenz, DrMedVet,
J. Cassidy, MVB,
Veterinary Sciences Centre, School
of Agriculture, Food Science and
Veterinary Medicine, University College
Dublin, Belfield, Dublin 4, Ireland

E-mail for correspondence:
scahalan@rvc.ac.uk

Provenance: not commissioned;
externally peer reviewed

Accepted July 27, 2012

On necropsy examination, animal A had a focal, circumscribed, raised, ulcerated lesion in the skin overlying and involving the right precrural lymph node (Fig 2). On sectioning, this lesion contained yellow foci measuring 1–2 cm in diameter ('sulphur' granules) within a dense fibrous stroma (Fig 3).

Diffuse circumferential subcutaneous oedema and fibrosis extended from the right stifle to the digits, with multifocal small 'sulphur' granules scattered throughout. Prominent, firm, raised, tortuous tracts were evident from the skin surface, consistent with chronic lymphangitis. Similar lesions were present in animal B without regional lymph node involvement.

Histopathological examination of the cutaneous lesions revealed multiple pyogranulomatous foci within the dermis and subcutis

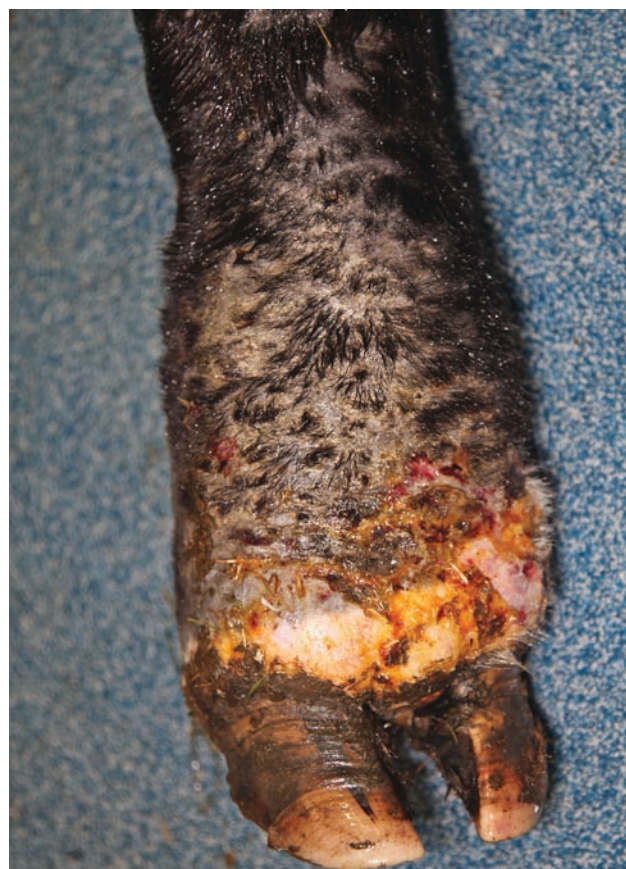

FIG 1: A cranial view of extensive, firm, diffuse, soft tissue swelling extending to the coronary band of animal A

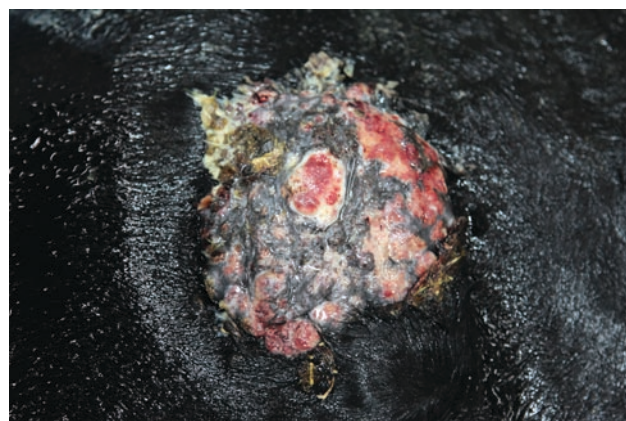


FIG 2: A circumscribed ulcerated lesion overlying the right precrural lymph node of animal A

Short Communications

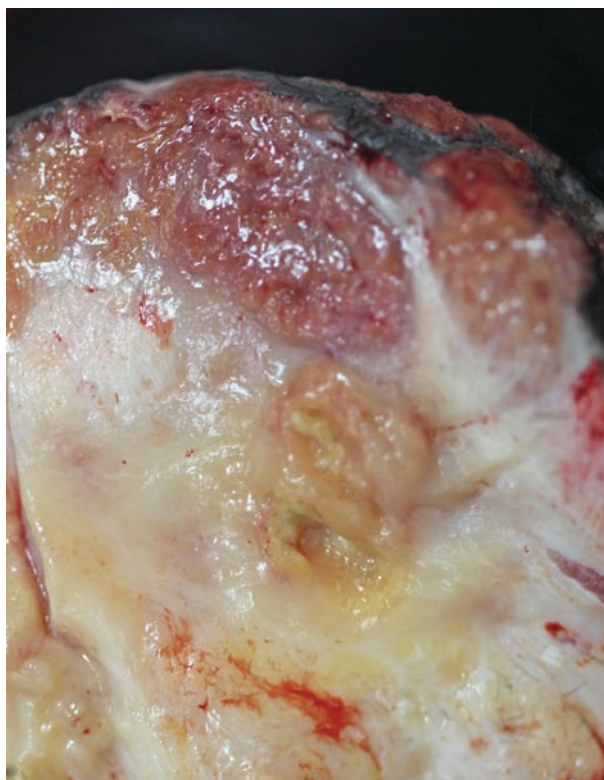


FIG 3: Yellow 'sulphur granules' within a dense fibrous stroma (animal A)

centred on densely clustered basophilic coccobacilli surrounded by radiating mantles of eosinophilic 'clubs'. These were surrounded by neutrophils, macrophages and multinucleate giant cells within a thick fibrous stroma. Similar pyogranulomas were noted in the capsule of the right precrural lymph node. *A. lignieresii* and *Staphylococcus aureus* were isolated from the precrural lymph node of the younger bullock using standard microbiological culture techniques (Quinn 2002).

Multiple cases of cutaneous actinobacillosis in cattle involving the limbs, and resulting in severe lameness, have not been previously reported. This atypical 'outbreak' is highly unusual given the high morbidity over a relatively short timeframe of 11 months. A previous report described circumscribed cutaneous nodules in the distal limbs of two cattle, however, lameness was not a reported feature (Holzhauer and Roumen 2002). Subclinical actinobacillosis is a relatively common incidental finding in cattle at slaughter, with characteristic involvement of the tongue and lymph nodes of the head (Herenda and Dukes 1988, Bradley and Jericho 1997); the disease is usually sporadic, involving small numbers of animals (Campbell and others 1975, Nakazawa and Azuma 1977, Radostits 2007, Bazargani and others 2010). In these cases, predisposing factors have included: the feeding of large amounts of dry fibrous hay, haylage, oat or wheat straw; crowded animal accommodation resulting in cutaneous injuries; and contamination of the animal environment and feed through discharging lesions and/or saliva (Campbell and others 1975, Smith 2009). Following detailed on-farm investigation in the current study, the fact that five cases of lingual actinobacillosis had occurred on the farm over the previous four years, together with the relatively high stocking density, were considered predisposing factors. No significant changes had been made to the diet or accommodation on this unit for a number of years prior to the outbreak.

The distribution of lesions over the distal limbs suggests the organism was transmitted through infected saliva during allo- or autogrooming, with the pathogen entering the skin through small percutaneous abrasions or wounds. Young cattle in particular, are susceptible following subcutaneous inoculation, and lesions can develop in a number of days (Rycroft and Garside 2000). *A. lignieresii*-infected surgical wounds have been reported in cattle following caesarean section (De Kruif and others 1992), and in humans following animal bites (Dibb and others 1981, Peel and others 1991). Inspection of the animal accommodation failed to reveal abrasive surfaces, edges or vegetation that could have

facilitated percutaneous infection. Since the outbreak some 18 months ago, the stocking rate on the premises has been reduced, with no further cases reported to date.

What role *S. aureus* played in this outbreak remains unclear, although the histopathological appearance of the lesions was highly characteristic of those associated with *A. lignieresii* infection. However, given that *S. aureus* results in pyogranuloma formation (botryomycosis) following wound infection in horses and pigs (McGavin 1995), its additional presence may have increased the severity of the lesions in this case.

Successful medical treatment of cutaneous actinobacillosis has been reported in the literature. Chronic cutaneous lesions in three animals responded well to a two- to four-week course of procaine penicillin and dihydrostreptomycin or streptomycin and dihydrostreptomycin (Milne and others 2001).

This 'outbreak' of cutaneous actinobacillosis involving the lower limbs of young cattle was atypical in the numbers of animals involved and the distribution of the lesions. Actinobacillosis should be considered in the differential diagnosis of firm cutaneous lesions on the limbs of cattle that present with lameness. Reduction of stocking density and identification and removal of potential sources of trauma within animal housing units are suggested control/prevention strategies.

Acknowledgements

I would like to thank Mr Paul Quinn for facilitating the farm inspection and providing detailed histories; Mr Brian Cloak for expertise in gross and histological photography; and Ms Yvonne Abbott and Bernadette Leggett for their work on the microbiological cultures.

References

- BAZARGANI, T. T., TAFTI, K. A., ATYABI, N. & EAGHANIZADEH, Gh. (2010) An unusual occurrence of actinobacillosis in heifers and cows in a dairy herd in tehran suburb-Iran. *Archives of Razi Institute* **65**, 105–110
- BRADLEY, J. A. & JERICHO, K. W. F. (1997) Risk assessment: abscessation of head lymph nodes and carcass inspection at two high-line-speed beef abattoirs in Western Canada. *Journal of Food Protection* **60**, 157–160
- CAMPBELL, S. G., WHITLOCK, R. H., TIMONEY, J. F., & UNDERWOOD, A. M. (1975) An unusual epizootic of actinobacillosis in dairy heifers. *Journal of American Veterinary Medicine Association* **166**, 604–606
- CARMALT, J. L., BAPTISTE, K. E. & CHIRINO-TREJO, J. M. (1999) *Actinobacillus lignieresii* infection in two horses. *Journal of American Veterinary Medical Association* **215**, 826–828
- DE KRUIF, A., DE MIJTEN, P., HAESEBROUCK, E., HOORENS, J. & DEVRIESE, L. (1992) Actinobacillosis in bovine caesarean sections. *Veterinary Record* **131**, 414–415
- DIBB, W. L., DIGRANES, A. & TONJUM, S. (1981) *Actinobacillus lignieresii* infection after a horse bite. *British Medical Journal* **283**, 583–584
- FUBINI, S. L. & CAMPBELL, S. G. (1983) External lumps on sheep and goats. *Veterinary Clinics of North America: Large Animal Practice* **5**, 457–476
- HEBELER, H. E., LINTON, A. H. & OSBORNE, A. D. (1961) Atypical actinobacillosis in a dairy herd. *Veterinary Record* **73**, 517–521
- HERENDA, D. & DUKES, T. W. (1988) Lymphoreticular lesions in beef cattle at an ontario abattoir. *Canadian Veterinary Journal* **29**, 730–734
- HOLZHAUER, M. & ROUMEN, T. P. H. M. (2002) Atypical actinobacillosis in a dairy replacement herd. *Veterinary Record* **151**, 276
- KENNERMAN, E., SALCI, H. & SEVIMILI, A. (2006) Case of systemic actinobacillosis in a dog-a case report. *Bulletin of the Veterinary Institute in Pulawy* **50**, 613–617
- MILNE, M. H., BARRETT, D. C., MELLOR, D. J. & FITZPATRICK, J. L. (2001) Clinical recognition and treatment of bovine cutaneous actinobacillosis. *Veterinary Record* **148**, 273–274
- MCGAVIN, M. D. (1995) Muscle. In Thomson's Special Veterinary Pathology. 2nd edn. Eds W. W. Carlton & M. D. McGavin. Mosby, pp 410
- MORTIMER, P. H. (1962) An extrathoracic oesophageal lesion, later attributed to actinobacillosis, causing unusual symptoms in a dairy cow. *Veterinary Record* **74**, 392–394
- MUHAMMAD, C., SAQIB, M. & ATHAR, M. (2006) Fatal actinobacillosis in a dairy Buffalo. *Acta Veterinaria BRNO* **75**, 247–250
- NAKAZAWA, M. & AZUMA, R. (1977) Collective outbreaks of bovine actinobacillosis. *Japanese Journal of Veterinary Science* **39**, 549–557
- PEEL, M. M., HORNIDGE, K. A., LUPPINO, M., STACPOOLE, A. M. & WEAVER, R. E. (1991) *Actinobacillus* spp. and related bacteria in infected wounds of human bitten by horses and sheep. *Journal of Clinical Microbiology* **29**, 2535–2538
- QUINN, P. J. (2002) *Actinobacillus* Species. In Veterinary Microbiology and Microbial Disease. 1st edn. Eds P. J. Quinn, B. K. Markey, M. E. Carter, W. J. Donnelly & F. C. Leonard. Blackwell Science, pp 131–132
- RADOSTITS, O. M. (2007) Diseases associated with *Actinomyces* spp, *Actinobacillus* spp, *Nocardia* spp, and *Dermatophilus* spp. In Veterinary Medicine. 10th edn. Eds O. M. Radostits, C. C. Gay, D. C. Blood & K. W. Hinchcliff. Saunders, pp 1046–1048
- RYCROFT, A. N. & GARSIDE, L. H. (2000) Actinobacillus species and their role in animal disease. *The Veterinary Journal* **159**, 18–36
- SMITH, B. P. (2009) Disease of the alimentary tract. In Large Animal Internal Medicine. 4th edn. Ed B. P. Smith. Mosby Elsevier, pp 782–784
- SWARBRICK, O. (1967) Atypical actinobacillosis in three cows. *British Veterinary Journal* **123**, 70–75



Atypical cutaneous actinobacillosis in young beef cattle

S. D. Cahalan, L. Sheridan, C. R. Akers, et al.

Veterinary Record published online August 22, 2012

doi: 10.1136/vr.100906

Updated information and services can be found at:

<http://veterinaryrecord.bmj.com/content/early/2012/08/21/vr.100906.full.html>

These include:

References

This article cites 18 articles, 4 of which can be accessed free at:

<http://veterinaryrecord.bmj.com/content/early/2012/08/21/vr.100906.full.html#ref-list-1>

P<P

Published online August 22, 2012 in advance of the print journal.

Email alerting service

Receive free email alerts when new articles cite this article. Sign up in the box at the top right corner of the online article.

Notes

Advance online articles have been peer reviewed, accepted for publication, edited and typeset, but have not yet appeared in the paper journal. Advance online articles are citable and establish publication priority; they are indexed by PubMed from initial publication. Citations to Advance online articles must include the digital object identifier (DOIs) and date of initial publication.

To request permissions go to:

<http://group.bmj.com/group/rights-licensing/permissions>

To order reprints go to:

<http://journals.bmj.com/cgi/reprintform>

To subscribe to BMJ go to:

<http://group.bmj.com/subscribe/>